

International Journal of Scientific Research and Reviews

Effect of Aflatoxin B1 and/ or Chlorpyrifos on The Reproduction of Male Wistar Rats

B. Akhila¹ and P. Sreenivasula Reddy^{2*}

¹ Department of Biotechnology, S. V. University, Tirupati 517 502, India

² Department of Zoology, S. V. University, Tirupati 517 502, India

ABSTRACT

Mycotoxins and pesticides are major contaminants that commonly co-occur in the agricultural products, and thus of important concern for human and animal health. The present study was designed to investigate the effect of aflatoxin B1 (AFB1) and/or chlorpyrifos (CPF) on reproduction in Wistar rats. For this purpose, 24 adult male rats were divided into four groups. Animals in group 1 were kept as control, while those in groups 2-4 were given CPF (13.5mg/kg b. wt) daily, AFB1 (55µg/kg b. wt) on alternate days and CPF+AFB1 respectively by gastric gavage for 60 days. The results revealed significant reduction in the weights of reproductive organs, epididymal sperm count, viable-, motile-, and HOS-tail coiled sperm and testicular daily sperm production in rats treated with either CPF or AFB1. Testicular 3β- and 17β-hydroxysteroid dehydrogenase activities and serum testosterone levels were also decreased significantly in rats treated with either CPF or AFB1. Conversely the levels of lipid peroxidation elevated significantly with decreased activity levels of superoxide dismutase and catalase in the testis of rats treated with either CPF or AFB1. Exposure to either CPF or AFB1 resulted in deterioration in testicular architecture with a reduction in epithelial thickness and seminiferous tubule diameter. The toxicological effects were more pronounced in the rats given both the chemicals in combination.

KEYWORDS: Chlorpyrifos, Aflatoxin B1, Sperm, Testosterone, Lipid peroxidation.

*** Corresponding Author:-**

Dr. P. Sreenivasula Reddy

Department of Zoology, Sri Venkateswara University

Tirupati- 517 502. India.

Tel: +91-877-2249320

FAX: +91-877-2249611

E-Mail: psreddy1955@gmail.com

1. INTRODUCTION

Every day more and more consumers, worldwide are becoming aware of food safety and the risks associated with its contamination by microorganisms and by toxic compounds¹. Mycotoxins and pesticides are major contaminants that commonly co-occur in agricultural products and thus of major concern for human and animal health. The indiscriminate use of pesticides and poor agricultural practices makes the occurrence of these substances above permissible levels in food and feed. The co-existence of mycotoxins and pesticides in food are associated with number of physiological alterations including reproductive disorders. Once these toxic chemicals are introduced into the environment, they travel beyond their point of application or discharge shows adverse effects on non-target organisms.

Chlorpyrifos is one of the environmental pollutants which potentially affect the male reproduction. Studies of Joshi et al.² suggested that prolonged exposure of chlorpyrifos alters semen quality and sperm chromatin, reduces sperm motility, viability and increases sperm morphological abnormalities and damage to vital organs. Another study of Shittuet al.³ reported a significant increase in malondialdehyde in the testis of chlorpyrifos treated rats indicating elevated oxidative stress. Some of the earlier studies have demonstrated that low testosterone production results in suppression of spermatogenesis⁴. Exposure to chlorpyrifos also resulted in seminiferous tubules shrinkage, rupture of epithelium and mild changes in spermatogenic cells in rats⁵⁻⁶.

Aflatoxin B1 is the most abundant mycotoxin in nature. 75% of the world population was exposed to aflatoxin B1, through contaminated food. Previous studies reported that Aflatoxins caused decrease in spermatogenesis and steroidogenesis, deterioration in testicular architecture, reduction in the weights of testes results in disrupted male reproductive structure and function⁷⁻¹⁴. Administration of aflatoxin B1 resulted in degenerative changes in seminiferous tubules and reduction in the number of mature spermatids in albino rats and rabbits¹⁵ and decreased sperm quality and quantity¹⁶. Oral administration of AFB1 (50µg/kgbw/day) for 35 days resulted in spermatotoxic effects on mouse epididymal sperm count, motility and sperm abnormalities⁷. Previous studies in our laboratory reported that AFB1 binds competitively to StAR protein there by interferes cholesterol transport into mitochondria resulting in reduced biosynthesis of testosterone¹⁷.

Although a large number of studies have been reported on deleterious effects of aflatoxin B1 and chlorpyrifos on reproduction individually, there have been no reports dealing particularly with the detrimental effects of combination of aflatoxin B1 and chlorpyrifos on reproduction. Since, these chemicals co-occur in food/feed in nature, the effect of co-exposure to AFB1 and CPF on reproduction in male Wistar rats was undertaken for the present study.

2. MATERIALS AND METHODS

2.1 Procurement and maintenance of experimental animals

Adult male Wistar strain rats with a body weight ranging from 200-230 gm (90 days old) were obtained from an authorized vendor (M/S Raghavendra Enterprises, Bengaluru, India). Upon arrival, rats were housed in polypropylene cages (47cm × 34cm × 20cm) containing sterile paddy husk as bedding material. All the animals were maintained under the controlled laboratory conditions temperature, 22-25°C, lighting, 12: 12h light: dark cycle. The rats were reared on a standard pellet diet (HLL Animal feed, Bengaluru, India) and tap water *ad libitum*. The experiments were carried out in accordance with the guidelines and protocol approved by the Institutional Animal Ethical Committee (Regd.No.438/01/a/CPCSEA/dt.17.07.2001), S. V. University, Tirupati.

2.2 Chemicals

Aflatoxin B1, dihydroepiandrosterone, androstenedione, bovine serum albumin (BSA), nicotinamide adenine dinucleotide (NAD) was purchased from Sigma Chemical Company, St. Louis, Missouri, USA. Chlorpyrifos was purchased from Bhagiradha Chemicals and Private Limited, Hyderabad, India. All other chemicals used in the study were of analytical grade and obtained from local commercial sources.

2.3 Experimental design

Rats were weighed and randomly divided into four groups, consisting of six rats per group, where the first group served as control and were allowed *ad libitum* access to tap water. Rats in the second group were dosed with CPF 13.5 mg/kg body weight (1/10 of LD 50)^{2, 18-19} daily for 60 days in 0.6ml of corn oil by oral gavage, while animals in third group received AFB1 (55 µg/kg body weight, 1/10 of LD 50) in 0.6 ml of DMSO by oral gavage in alternate days for 60 days. The dosage levels of AFB1 were based on previous studies on rats^{7-8, 17, 20-21}. Rats in fourth group were received both CPF and AFB1 as in group 2 and 3. Both control and experimental rats were fasted overnight, and killed by cervical dislocation on the day following the last treatment. Testes and other reproductive organs were isolated and weighed after clearing off the adhering tissues. Tissue somatic index (TSI) was calculated using following formula:

$$\text{TSI} = \text{weight of the tissue (g)} / \text{body weight of the animal (g)} \times 100.$$

Testes were used for determination of daily sperm production, biochemical analysis and histological changes where ascaudaepididymides were used for sperm analysis.

2.4 Sperm analysis

Epididymal sperms were counted by using a Neubauerhaemocytometer as described by Belsey et al.²², within 5 min following their isolation from cauda epididymis at 37°C and the data were express as millions/ml. The motility of sperm was observed on a Neubauer chamber and the data expressed as a percentage of motile sperm of the total sperm counted by Belsey et al.²². The number of viable sperms was determined using 1% tryphan blue reagent²³. The membrane integrity of the sperm was determined by exposing the sperms in hypo osmotic solution and observed for coiled tails under the microscope and the percent of coiling was estimated using the method described by Jayendran et al.²⁴. Daily sperm production was determined in the testes of adult rats by the method of Blazaket al.²⁵ and the numbers of sperm were express as millions per gram.

2.5 Assay of Steriodogenic marker enzymes

The testicular tissue was homogenized in ice-cold Tris-HCl (pH 6.8). The microsomal fraction was separated and used as the enzyme source. The activity levels of (3β-HSD) (EC 1.1.1.51) and (17β-HSD) (EC 1.1.1.61) were determined by the method described by Bergmeyer²⁶ and expressed as nmol of NAD converted to NADH/mg/protein/min (3β- HSD) or nmol of NADPH converted to NADP/ mg protein/ min (17β-HSD). Protein content in the enzyme source was estimated by the method of Lowry et al.²⁷ using bovine serum albumin as standard.

2.6 Determination of lipid peroxidation

The levels of lipid peroxidation in the testis was measured in terms of malondialdehyde (MDA; a broken product of lipid peroxidation) content and determined by using the thiobarbituric acid (TBA) reagent. The reactivity of TBA is determined with minor modifications of the method adopted by Hiroshi et al.²⁸.

2.7 Assay of anti-oxidant enzyme activities

Superoxide dismutase (EC 1.15.1.1) was assayed by the method of Mishra and Fridovich²⁹ according to its ability to inhibit the auto oxidation of epinephrine at alkaline medium. The activity of SOD was expressed in units/mg protein/min. Catalase (EC 1.11.1.6) activity was determined according to its ability to decompose H₂O₂³⁰ and expressed in μmol of hydrogen peroxide consumed/mg protein/min.

2.8 Determination of serum hormonal measurements

Serum level of testosterone was determined by Chemiluminescent immunoassay (CLIA) by using autobiotesto kit (catalog number is CL1104-2) purchased from Autobio diagnostic Co. Ltd, China. The sensitivity of the assay was calculated as 0.002ng and intra assay variation was found to be 6.75%.

2.9 Histological evaluation of testes

The right testis was collected from control and experimental rats and fixed individually in Bouin's solution for 24 h. The fixed specimens were dehydrated in ascending alcohol series and after clearing in xylol, embedded in paraffin wax. Sections at 6 microns thickness were cut and stained with hematoxylin and eosin⁶.

2.10 Statistical analysis

The data were statistically analyzed using one-way analysis of variance (ANOVA) followed by Tukey-alpha multiple comparison test using the Statistical Package for Social Sciences (SPSS) 20 version. The data were presented as mean \pm S.D. Differences were considered to be significant at $p < 0.05$.

3. RESULTS AND DISCUSSION

All the animals were apparently normal and no unusual behaviors like circling, head searching, facial movements, head searching, licking, biting were observed in any of the rats. None of the control or experimental rats died or was excluded from the experiment. There was no significant change in body weight gain between the groups, however, significant decrease was observed in the rats treated with combination of CPF and AFB1 indicating absence of overt general toxicity in CPF+AFB1 treated rats (Table No.1).

The weights of testes and other reproductive organs like epididymis, seminal vesicles, prostate gland and vas deferens decreased significantly ($p < 0.05$) in AFB1 treated rats (TableNo.2). The observed decrease in the testes weight may be due to degeneration of the epithelium, decrease in the size and thickness of the germinal layer in the seminiferous tubules. The reduction in weight of testes recorded in AFB1 treated rats is in agreement with earlier reports^{12, 15, 17, 31}. It was observed a significant ($p < 0.05$) decrease in spermatogenesis (TableNo.3) in the rats treated with AFB1, these results are in agreement with earlier reports^{10-11, 31-32}. Sperm production and maturation depends on bioavailability of testosterone. The levels of testosterone in circulation decreased significantly ($p < 0.05$) in AFB1 exposed rats. In the present study exposure to AFB1 significantly ($p < 0.05$) reduced

daily sperm production, epididymal sperm count, motile, viable and HOS tail coiled sperms, similar results were observed earlier^{7-10, 12, 14, 17}. The sperm membrane integrity can be evidenced from the HOS test, which also indicates the deteriorated sperm membrane integrity in AFB1 treated rats.

The activity levels of testicular 3 β -HSD and 17 β -HSD were significantly ($p < 0.05$) decreased in the AFB1 treated animals (Table No.4) indicating decreased steroidogenesis. Salem et al.¹², Hasanzadeh et al.³³ reported that long term AFB1 exposure results in reduced serum testosterone levels and increased serum LH concentration. Thus, the decrease in serum testosterone levels could be due to the diminished responsiveness of leydig cells to LH and/or direct inhibition of testosterone synthesis in rats exposed to AFB1.

The levels of malondialdehyde revealed increased significantly ($p < 0.05$) in the testes of rats treated with AFB1 (Table No. 5). On the other hand, the activity levels of SOD and catalase decreased significantly ($p < 0.05$) in the testes of rats exposed to AFB1 (Table No.5). The deterioration in the selected sperm parameters may be increased oxidative stress during AFB1 intoxication, in agreement with the studies of ThnaianAlthnaianet al.³⁴. Exposure to AFB1 induced testicular oxidative stress as evidenced by increased levels of lipid peroxidation and decreased activities of SOD¹ and catalase^{21, 32}. The histopathological finding reported in the current study is degenerative changes and reduce the number of spermatocytes, spermatids in the testes of rats intoxicated with AFB1. Similar histopathological changes of aflatoxin induced testicular damage have been previously reported in rats^{11, 35-36}.

CPF at the selected dose did not cause any significant change in the body weight gain indicating did not change the metabolic activity in CPF treated rats (Table No.1). In the present study, CPF for 60 days resulted in a significant ($p < 0.05$) decrease epididymis and testicular weight (Table No.2), similar results were observed earlier by Afafet al.³⁷. In the present study, daily sperm production, epididymal sperm count, viable sperms, motile sperms and HOS tail coiled sperm were also significantly ($p < 0.05$) decreased in the rats treated with CPF as compared to control rats (Table No.3). Further, the decrease in percent number of tail-coiled sperms as evidenced by hypoosmotic swelling test suggests that membrane integrity of the sperm is deteriorated. Similar decreases in sperm quality and quantity of sperm were reported in rats exposed to CPF³⁸⁻⁴⁰. In the present study, exposure of rats to CPF for 60 days is characterized by a significant ($p < 0.05$) increase in the levels of lipid peroxidation in the testes as compared to control rats. The circulatory levels of testosterone and activity levels of steroidogenic enzymes were significantly ($p < 0.05$) decreased in the testis of CPF treated rats as compared to control rats (Table No.4) indicating decreased steroidogenesis.

Therefore, the decline observed in daily sperm production and epididymal sperm count as compared to control rats may be the consequence of the reduced testosterone secretion from leydig cells in CPF treated rats. The present results are in agreement with previous studies^{2-3, 41-42}. This is because low testosterone production results in suppression of spermatogenesis. Cal EPA⁴³ reported studies showing that exposure to CPF have caused DNA damage in sperm, decreased sperm motility and decreased testosterone and estradiol levels in men. The significant ($p < 0.05$) increase in malandialdehyde in the testes of CPF treated rats indicates oxidative stress to these tissues (TableNo.5). On the other hand, the activity levels of SOD and catalase decreased significantly ($p < 0.05$) in the testes of rats exposed to AFB1(TableNo.5). Similar results have been obtained earlier³ in the testes of rats intoxicated with CPF. Histopathological changes of testes showed a decrease in the number of seminiferous tubules form shrinkage, rupture of epithelium and increased intertubular spaces and mild changes in spermatogenic cells of rats treated with CFP (Figure No.1B). The results of the present study were in agreement with earlier reports⁵⁻⁶.

In the present work has shown that exposure of rats to both CPF and AFB1, significant decrease in body weight gain (TableNo.1) and relative weights of testes and other reproductive organs (Table No.2) indicating presence of overt general toxicity. The decrease in the weight of the testes may be due to degeneration of germinal epithelium. The morphology and functional integrity of the testis and accessory sex organs are dependent on availability of androgens. Decrease in daily sperm production, epididymal sperm count, viable, motile and HOS tail coiled sperms and testis volume were more pronounced in CPF+AFB1 in rats and is significant ($p < 0.05$) decrease as compared to rats treated with CFP or AFB1 alone (Table No.3). Our results also indicated that the decrease in weight of testis, and accessory sex organs is more prominent in rats treated with CPF+AFB1. The data also reveal a statistically significant ($p < 0.05$) decrease in the activity levels of 3β - and 17β -HSD in the testes, associated with significantly reduced serum testosterone levels in rats administered with CPF+AFB1, indicating a probable inhibition of androgen synthesis in experimental rats (Table No.4). The mechanism(s) of action CPF and AFB1 is indicating and they showed synergistic effects in inhibiting steroidogenesis and spermatogenesis, including oxidative toxicity in testes. In addition, pronounced decrease was observed in testicular steroidogenic enzyme activities, SOD and catalase and serum testosterone levels in CPF+AFB1 rats when compared to CPF or AFB1 (Table No. 5). Histopathological changes of testes showed a decrease in the number of seminiferous tubules rupture of epithelium, spermatogenic cells and increased intertubular spaces and loss of structural integrity of testicular architecture in rats treated with CFP+AFB1 (Figure No.1D).

Table No.1: Body weights (g) of control rats and rats exposed to CPF and/or AFB1

Parameters	Control	CPF	AFB1	CPF+AFB1
Initial Body weight (g)	211.00 ^a ± 3.41	212.66 ^a ± 6.08 (0.79)	209.25 ^a ± 6.73 (0.83)	214.92 ^a ± 6.18 (1.85)
Final Body weight (g)	271.83 ^a ± 10.55	259.7 ^a ± 5.16 (-4.46)	255.08 ^a ± 9.9 (-5.82)	249.33 ^b ± 8.3 (-6.16)
Weight gain (g)	60.83 ^a ± 11.65	47.04 ^a ± 8.75	45.91 ^a ± 12.70	34.50 ^b ± 7.42

Values are mean ± S.D of six individuals

Values in the parentheses are percent change from that of control

Mean values that do not share same superscript in a row differ significantly from each other at p< 0.05

Table No.2: Tissue indices (W/W %) of rats exposed to CPF and/or AFB1

Tissue	Control	CPF	AFB1	CPF+AFB1
Testes	1.86 ^a ± 0.10	0.96 ^b ± 0.45 (-48.38)	0.98 ^b ± 0.19 (-47.31)	0.91 ^c ± 0.19 (-51.07)
Cauda epididymis	0.17 ^a ± 0.05	0.10 ^b ± 0.02 (-41.18)	0.11 ^b ± 0.02 (-35.29)	0.09 ^c ± 0.02 (-47.06)
Caput epididymis	1.59 ^a ± 0.11	0.90 ^b ± 0.11 (-43.40)	0.92 ^b ± 0.08 (42.13)	0.65 ^c ± 0.16 (-58.7)
Corpus epididymis	0.09 ^a ± 0.03	0.09 ^a ± 0.01 (0)	0.08 ^a ± 0.03 (-11.11)	0.08 ^a ± 0.03 (-11.11)
Seminal vesicle	0.45 ± 0.15	0.28 ^b ± 0.04 (-37.77)	0.26 ^b ± 0.03 (-42.22)	0.23 ^b ± 0.09 (-48.88)
Prostate gland	0.19 ^a ± 0.05	0.13 ^a ± 0.04 (-31.58)	0.12 ^b ± 0.03 (-36.84)	0.10 ^b ± 0.03 (-47.36)
Vas deferens	0.18 ^a ± 0.03	0.09 ^b ± 0.02 (-50.0)	0.07 ^b ± 0.02 (-61.11)	0.07 ^b ± 0.03 (-61.11)
Penis	0.16 ^a ± 0.01	0.09 ^b ± 0.01 (-43.75)	0.09 ^b ± 0.06 (-43.75)	0.08 ^b ± 0.05 (-50)

Values are mean ± S.D of six individuals

Values in the parentheses are percent decrease from that of control

Mean values that do not share same superscript in a row differ significantly from each other at p< 0.05

Table No. 3: Daily sperm production, epididymal sperm count, motile, viable and HOS tail coiled sperms and testis volume of rats exposed to CPF and/or AFB1

Parameters	Control	CPF	AFB1	CPF+AFB1
DSP (millions/gram testis)	22.5 ^a ± 1.05	14.83 ^b ± 0.75 (-34.09)	14.81 ^b ± 0.74 (-34.18)	12.26 ^c ± 0.78 (-45.51)
Sperm count (millions/ml)	58.89 ^a ± 4.48	36.46 ^b ± 3.25 (-38.09)	35.73 ^b ± 3.57 (-39.33)	29.61 ^c ± 3.17 (-49.72)
Motile sperm (%)	65.16 ^a ± 3.31	42.58 ^b ± 2.17 (-34.65)	38.58 ^b ± 2.15 (-40.79)	28.06 ^c ± 2.24 (-56.94)
Viable sperm (%)	69.80 ^a ± 3.92	47.11 ^b ± 2.36 (-32.51)	41.25 ^c ± 2.87 (-40.90)	38.10 ^c ± 2.79 (-45.41)
HOS tail coiled sperm (%)	57.82 ^a ± 5.30	41.35 ^b ± 3.68 (-28.48)	40.90 ^b ± 3.55 (-29.26)	32.48 ^c ± 2.62 (-43.83)
Testes volume (ml)	1.28 ^a ± 0.20	0.85 ^b ± 0.17 (-33.59)	0.78 ^b ± 0.18 (-39.06)	0.66 ^b ± 0.21 (-48.43)

Values are mean ± S.D of six individuals

Values in the parentheses are percent decrease from that of control.

Mean values that do not share same superscript in a row differ significantly from each other at p< 0.05

Table No.4: 3β- and 17β- hydroxysteroid dehydrogenase activity levels in the testis and testosterone levels in circulation of rats exposed to CPF and/or AFB1

Enzyme	Control	CPF	AFB1	CPF + AFB1
3βHSD (μmoles of NAD converted to NADH/mg protein/min)	3.82 ^a ± 0.56	0.73 ^b ± 0.23 (-80.89)	0.42 ^c ± 0.27 (-89.0)	0.10 ^c ± 0.03 (-97.38)
17βHSD (μmoles of NADPH converted to NADP/mg protein/min)	4.48 ^a ± 0.67	1.80 ^b ± 0.93 (-59.82)	1.21 ^b ± 0.87 (-72.99)	1.16 ^b ± 0.76 (-74.10)
Testosterone (ng/ml)	4.85 ^a ± 0.58	2.33 ^b ± 0.26 (-51.96)	1.17 ^c ± 0.10 (-75.87)	0.29 ^d ± 0.21 (-94.02)

Values are mean ± S.D of six individuals

Values in the parentheses are percent decrease from that of control.

Mean values that do not share same superscript in a row differ significantly from each other at $p < 0.05$

Table No.5: Levels of lipid peroxidation and activity levels of superoxide dismutase and catalase in testis of rats exposed to CPF and/or AFB1

Parameters	Control	CPF	AFB1	CPF + AFB1
Lipid peroxidation (μ moles of Mda formed/g tissue)	4.84 ^a ± 1.08	9.39 ^b ± 2.04 (101.72)	11.18 ^b ± 1.94 (139.91)	14.57 ^c ± 2.03 (212.66)
Superoxide dismutase (units/mg protein/min)	16.84 ^a ± 1.75	8.81 ^b ± 0.94 (-51.28)	8.98 ^b ± 2.16 (-46.38)	6.25 ^b ± 1.57 (-62.64)
Catalase (μ moles of H ₂ O ₂ metabolized/mg protein/min)	0.49 ^a ± 0.03	0.29 ^b ± 0.03 (-40.82)	0.27 ^b ± 0.01 (-44.89)	0.14 ^c ± 0.02 (-71.43)

Values are mean ± S.D of six individuals

Values in the parentheses are percent change from that of control.

Mean values that do not share same superscript in a row differ significantly from each other at $p < 0.05$

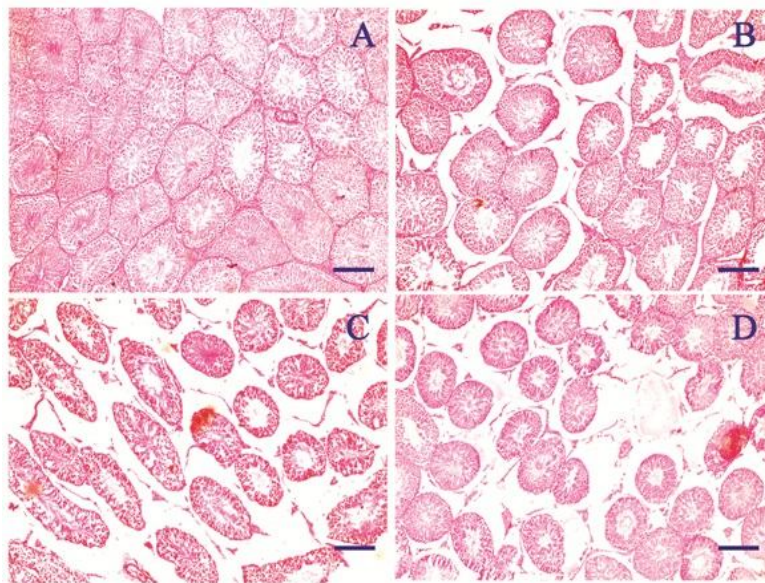


Figure No.1: Photomicrographs of testis of control rat (A), and rats exposed to CPF (B), AFB1 (C) and combination of CPF+AFB1 (D), Bar=50 μ m

4. CONCLUSION

Exposure to chlorpyrifos and aflatoxin B1 is responsible for reduction in spermatogenesis, steroidogenesis with an induction of oxidative stress in the testis of rats and decreased weights of testes, cauda epididymis, caput epididymis, seminal vesicles and prostate gland, penis and decreased sperm count, motile sperms, viable sperms and daily sperm production in adult male rats. In conclusion, this study provides compelling evidence of decreased steroidogenesis and spermatogenesis in adult rats that were administered with either CPF or AFB1 from early puberty. The maximum suppression in steroidogenesis and spermatogenesis was observed in double stressed rats. Further, exposure to combination of AFB1 and CPF showed additional deterioration in selected reproductive end points. In nature, humans are exposure to varieties of stresses simultaneously, hence there is an emergent need to re-establish safe levels of natural/ manmade chemicals in food stuffs and water for determining the associated risk to human and wild life.

5. ACKNOWLEDGEMENTS

The authors are thankful to the Head, Department of Zoology, S.V.University, Tirupati for providing the laboratory and animal facilities. The authors declare that the experiments conducted during these studies comply with current laws of their country and were approved by the Institutional Animal Ethical Committee at S.V.University, Tirupati, India.

6. DECLARATION OF CONFLICTING INTERESTS

The authors declare that there are no conflicts of interest that would prejudice the impartiality of this scientific work.

7. REFERENCES

1. Kher SV, De Jonge J, Wentholt MTA et al. Consumer perceptions of risks of chemical and microbiological contaminants associated with food chains: a cross-national study. *Int J. Consum. Stud.* 2013; 37: 73–83.
2. Joshi S, Mathur R, Gulati N. Testicular toxicity of chlorpyrifos (an organophosphate pesticide) in albino rat. *Toxicol. Ind. Health.* 2007; 23: 439-44.
3. Shittu M, Ambali SF, Ayo JO et al. Evaluation of chronic Chlorpyrifos-induced reproductive toxicity in male wistar rats. Protective effects of vitamin C. *J. Exp. Integr. Med.* 2013; 3: 23-30.
4. Heikal TM, Mossa ATH, Ibrahim AW, Abdel-Hamid HF. Oxidative damage and reproductive toxicity associated with cyromazine and chlorpyrifos in male rats: The protective effects of green tea extract. *Res. J. Environ. Toxicol.* 2014; 8:53-67.

5. Kalender Y, Kaya S, Durak D. Protective effects of catechin and quercetin on antioxidant status, lipid peroxidation and testishistoarchitecture induced by chlorpyrifos in male rats. *Environ. Toxicol. Pharmacol.* 2012; 33: 141–148.
6. RachidMosbah, Mokhtar Ibrahim Yousef, Francesca Maranghi, Alberto Mantovani. Protective role of *Nigella sativa* oil against reproductive toxicity, hormonal alterations, and oxidative damage induced by chlorpyrifos in male rats. *Toxicol. Ind. Health.* 2014; 32: 1266-1277.
7. Agnes VF, Akbarsha MA. Spermatotoxic effect of aflatoxin B (1) in albino mouse. *Food. Chem. Toxicol.* 2003; 41: 119-130.
8. Faridha A, Faisal K, Akbarsha MA. Aflatoxin treatment brings about generation of multinucleate giant spermatids (symplasts) through opening of cytoplasmic bridges: light and transmission electron microscopic study in Swiss mouse. *Reprod. Toxicol.* 2007; 24: 403-408.
9. Kourousekos GD, Theodosiadou EK. Effects of aflatoxins on male reproductive system: A review. *J. Hellenic. Vet. Med. Soc.* 2015; 66, 4.
10. Mathuria N, Verma RJ. Curcumin ameliorates aflatoxin-induced toxicity in mice spermatozoa. *Fertil. Steril.* 2008; 90: 775-780.
11. Murad AF, Ahmed S, Abead S. Toxicity effect of aflatoxin B1 on reproductive system of albino male rats. *Pak. J. Biol. Sci.* 2015; 18: 107-114.
12. Salem MH, Kamel KI, Yousef MI, Hassan GA. Protective role of ascorbic acid to enhance semen quality in rabbits treated with sublethal doses of aflatoxin B1. *Toxicology.* 2001; 162: 209-218.
13. Supriya CH, Reddy PS. Prenatal exposure to Aflatoxin B1: developmental, behavioral and reproductive alteration in male rats. *The Science of Nature.* 2015; 102:26.
14. Tajik P, Mirshokraee P, Khosravi A. Effects of different concentrations of aflatoxin B1 on ram epididymal and ejaculatory sperm viability and motility in vitro. *Pak. J. Biol. Sci.* 2007; 10: 4500-4504.
15. Lakkawar AW, Chattopadhyay SK, Johri TS. Experimental aflatoxin B1 toxicosis in young rabbits-a clinical and patho-anatomical study. *Slov. Vet. Res.* 2004; 41: 73-81.
16. Peiris DC, Dhanushka T. Low doses of chlorpyrifos interfere with spermatogenesis of rats through reduction of sex hormones. *Environ. Sci. Pollut. Res. Int.* 2017; 24:20859-20867.
17. Supriya CH, Girish BP, Sreenivasula Reddy P. Aflatoxin B1-Induced reproductive toxicity in male Rats: Possible Mechanism of Action. *Int. J. Toxicol.* 2014; 33:155-161.
18. AbirLalDutta, ChittaRanjanSahu. “*Emblica officinalis* Garten fruits extract ameliorates reproductive injury and oxidative testicular toxicity induced by chlorpyrifos in male rats”. 2013. Available from: URL: <https://doi.org/10.1186/2193-1801-2-541>.

19. U.S. EPA. Toxicology chapter for chlorpyrifos. A report of United States Environmental Protection Agency Washington DC; 2000: 1-52.
20. Gopal T, Oehme FW, Liao TF, Chen CL. Effects of intratesticular aflatoxin B1 on rat testes and blood estrogens. *Toxicol Lett.* 1980; 5: 263-267.
21. Verma RJ, Nair A. Effect of aflatoxins on testicular steroidogenesis and amelioration by vitamin E. *Food Chem. Toxicol.* 2002; 40: 669-672.
22. Belsey MA, Moghissi KS, Eliasson R, Paulsen CA, Callegos AJ, Prasad MRN. "Laboratory manual for the examination of human semen and semen-cervical mucus interaction". Press concern Singapore; 1980: p 10.
23. Talbot P, Chacon RS. A triple stain technique for evaluating normal acrosome reaction of human sperm. *J. Exp. Zool.* 1981; 215-201-208.
24. Jayendran RS, Van Der Ven HH, Zaneveld LJD. The hypo-osmotic swelling test: An update. *Arch. Androl.* 1992; 29: 105-116.
25. Blazak WF, Treinen KA, Juniewicz PE. Application of testicular sperm head counts in the assessment of male reproductive toxicity. *Methods Toxicol.* 1993; 3: 86-94.
26. Bergmayer HU. " β -hydroxysteroid dehydrogenases. Bergmayer HU (ed). In: *Methods of enzymatic analysis*". Academic Press, New York; 1974; 1: 447-489.
27. Lowry H, Rosebrough NI, Far AL, Ranall RJ. Protein measurement with folinphenol reagent. *J. Biol. Chem.* 1951; 193: 265-275.
28. Hiroshi O, Ohishi N, Yagi K. Assay of lipid peroxides in animal tissues by thiobarbituric acid reaction. *Annu. Rev. Biochem.* 1979; 95: 351-8.
29. Misra HP, Fridovich I. The role of superoxide anion in the autooxidation of epinephrine and a simple assay for superoxide dismutase. *J. Biol. Chem.* 1972; 247: 3170-3175.
30. Chance B, Machly AC. Assay of catalase and peroxidase. *Methods Enzymol.* 1955; 2: 764-775.
31. Ortatatlı M, Ciftci MK, Tuzcu M, Kaya A. The effects of aflatoxin on the reproductive system of roosters. *Res. Vet. Sci.* 2002; 72: 29-36.
32. Abu El-Saad AS, Mahmoud HM. Phytic acid exposure alters aflatoxin B1-induced reproductive and oxidative toxicity in albino Rats (*Rattus norvegicus*). *Evid. Based. Complement. Altern. Med.* 2009; 6: 331-341.
33. Hasanzadeh SH, Hosseini E, Rezazadeh L. Effects of aflatoxin B1 on profiles of gonadotropic (FSH and LH), steroid (testosterone and 17β -estradiol) and prolactin hormones in adult male rat. *Ira J. Vet Res.* 2011; 12:37.

34. ThnaianAlthnaian, Ibrahim Albokhadaim, Sabry M-El-Bahr. Effect of aflatoxin B1 on histopathology and oxidative stress biomarkers in testis of rats with special references to gene expression of antioxidant enzymes. *Int. J. Pharmacol.* 2016; 12: 408-412.
 35. El-Kordy EA, Abo Gazia MM. Effect of aflatoxin B1 on the seminiferous tubules and the possible protective role of curcumin in adult albino rats (light and electron microscopic study). *Egypt. J. Histol.* 2015; 38: 614-628.
 36. Tas M, Saruhan BG, Kurt D, Yokus B, Denli M. Protective role of lycopene on aflatoxin B1 induced changes sperm characteristics and testicular damages in rats. *Kafkas Univ. Vet. Fak. Derg.* 2010; 16- 597-604.
 37. Afaf EA, Hanam AT. Chlorpyrifos (from different sources): effect on testicular biochemistry of male albino rats. *Am. J. Sci.* 2010; 6: 252-261.
 38. Peiris DC, Dhanushka T. Low doses of chlorpyrifos interfere with spermatogenesis of rats through reduction of sex hormones. *Environ. Sci. Pollut. Res. Int.* 2017; 24:20859-20867.
 39. Sai L, Li X, Liu Y, Guo Q, Xie L. Effects of chlorpyrifos on reproductive toxicology of male rats. *Environ. Toxicol.* 2014; 29:1083-1088.
 40. Zidan NA. Evaluation of the reproductive toxicity of chlorpyrifos methyl, diazinon and profenofos pesticides in male rats. *Int. J. Clin. Pharmacol. Ther.* 2009; 5: 51-57.
 41. ElMazoudy RH, Attia AA. Endocrine-disrupting and cytotoxic potential of anti cholinesterase insecticide, diazinon in reproductive toxicity of male mice. *J. Hazard. Mater.* 2012; 209–210:111–20.
 42. Heikal TM, Mossa ATH, Ibrahim AW, Abdel-Hamid HF. Oxidative damage and reproductive toxicity associated with cyromazine and chlorpyrifos in male rats: The protective effects of green tea extract. *Res. J. Environ. Toxicol.* 2014; 8:53-67.
 43. Cal EPA. “Evidence on the developmental and reproductive toxicity of chlorpyrifos. Reproductive and cancer hazard assessment branch, office of environmental health hazard assessment, California Environmental Protection Agency”. 2008.
Available from: URL: [http:// oehha.ca.gov / prop65 /hazard_ident / pdf_zip / chlorpyrifos HID0908](http://oehha.ca.gov/prop65/hazard_ident/pdf_zip/chlorpyrifos/HID0908).
-