

## *International Journal of Scientific Research and Reviews*

### **Endodontic File Retrieval -A Minimal Interventional Approach**

**Shetty C.<sup>1</sup>, Sadananda V.<sup>2\*</sup>, Hegde M. N.<sup>3</sup>, Bhat G.S.<sup>4</sup>, Raghavan P.<sup>5</sup>, Shetty S.<sup>6</sup>**

<sup>1-6</sup>Department of Conservative Dentistry and Endodontics, A. B. Shetty Memorial Institute of Dental Sciences, Nitte (Deemed to be University), Deralakatte, Mangaluru – 575018, Karnataka, India.

---

#### **ABSTRACT:**

One of the most common mishaps that occur during routine Endodontic treatment is the fracture of instrument in the canal which causes obstruction and thereby prevents thorough cleaning and shaping. There are various advanced techniques and method to retrieve the broken instrument. But these techniques may not be applicable to all clinical situations where the availability of the advanced instruments is minimal. This paper reports a clinical scenario in a rural centre set up where the broken file from a lower right molar was retrieved using Endodontic hand instruments.

**KEY WORDS:** Endodontic treatment, broken instrument, retrieval

---

#### **\*Corresponding Author**

**Dr. Vandana Sadananda**

Lecturer, Department of Conservative Dentistry and Endodontics,

A. B. Shetty Memorial Institute of Dental Sciences,

Nitte (Deemed to be University), Deralakatte, Mangaluru – 575018, Karnataka, India.

E Mail - [vandanasadananda@gmail.com](mailto:vandanasadananda@gmail.com)

## **INTRODUCTION:**

Procedural mishaps can occur during any step of root canal during cleaning and shaping that might affect the prognosis of treatment. Examples of procedural include treatment of wrong tooth, breach of sterilization protocol, improper access, missed canals, ledge formation, artificial canal creation, root perforation, fracture of instruments and extrusion of irrigating solutions periapically<sup>1</sup>.

Fracture of instruments in the canal is one of the most troublesome incidents in endodontic therapy especially if the fragments cannot be removed. This can transform a case from whatever level of difficulty it was preoperatively to a level of severity<sup>2</sup>. Variants in root canal anatomy and jaws of a particular patient have always been unmodified factors that caused an endodontic file breakage. But now, iatrogenic factor has also been an important cause that can also lead to endodontic file breakage<sup>3</sup>. The common causes due to iatrogenic separation are improper use, limitations in physical properties, inadequate access, root canal anatomy and possibly manufacturing defects<sup>4</sup>.

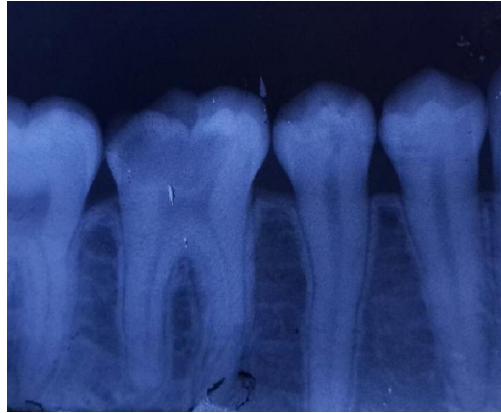
If the instrument separates there are three modalities of handling- retrieval, bypassing and sealing the fragment within the root canal or leaving the fragment in the canal and obturating till the instrument<sup>1</sup>. Many techniques have been advocated for such problems. Depending upon the site of separation treatment modality varies from the use of simple hand instruments to instrument retrieval kits or ultrasonics<sup>5</sup>.

This case report is based on an iatrogenic endodontic file breakage in the lower right first molar at a rural centre where the only option of file retrieval technique was using the available hand instruments

## **CASE REPORT:**

An 18-year-old female reported to our one of the rural centre with the chief complain of severe pain with respect to the lower right tooth since two days. On clinical examination there was a deep class II caries lesion involving the distobuccal aspect of the tooth and which was tender on percussion.

Radiographic examination showed radiolucency involving the enamel dentin and pulpal horns with no periapical changes.

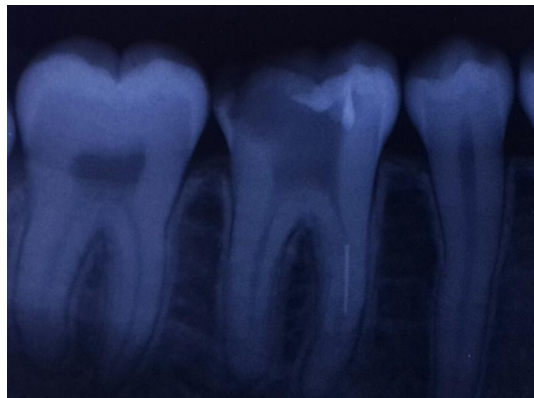


**Figure 1: Post- operative radiograph showing the decay involving the distobuccal area of 46**

The final diagnosis was acute pulpitis and the treatment plan was conventional root canal treatment

First appointment: Access opening was done under local anesthesia. All the three canals were located and pulp extirpation was done by using barbed broaches. Patient was sent back by giving an open dressing using cotton soaked in formocresol. Patient was recalled after one week for biomechanical preparation and working length estimation.

Second appointment: Patient came after one week with no symptoms of pain. She was prepared for biomechanical preparation and working length estimation was made in approximate basis using conventional radiograph. During the biomechanical preparation, accidentally K file no: 25 separated in the mesiobuccal canal. Patient was informed about the accident and was sent back with a closed dressing of zinc oxide eugenol.



**Figure 2: Radiograph showing file no 25 broken in the mesiobuccal canal of 46**

Third appointment: Patient was recalled after three days and file retrieval was done successfully and sent back with a closed dressing for the next appointment.

Method of file retrieval: Broken file was bypassed by using the smaller no K files starting from no: 10 and advanced till file no: 15 where the tactile sensation was attained and the broken file was successfully bypassed. Then using the smaller no H file (Hedstromfiles) the broken file was engaged and with the slow upward motion retrieval was achieved.

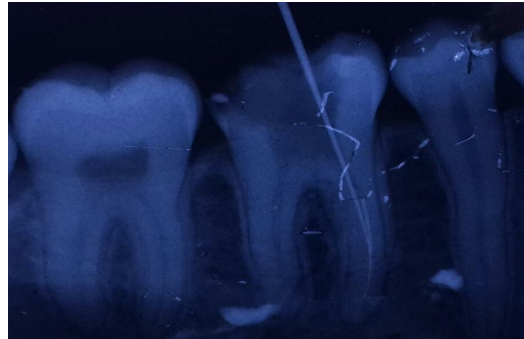

Figure3: Radiograph showing the broken file was bypassed using no:15 K file


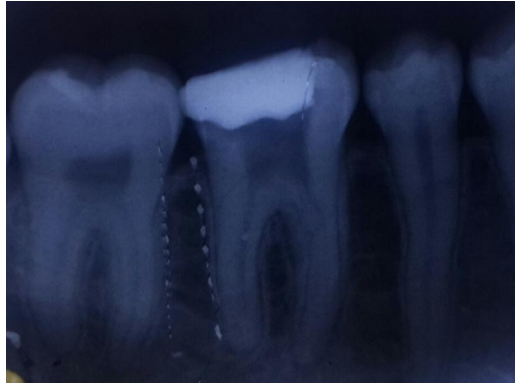


Figure 4: Broken file tip measuring around 4mm retrieved from the mesiobuccal canal



**Figure 4: Post-operative radiograph showing successful file retrieval from the canal and closed dressing using zinc oxide eugenol**

In the subsequent appointment biomechanical preparation and obturation of all three canals was achieved. Full metallic crown was placed finally.

## **DISCUSSION:**

Intracanal separation of the instrument usually prevent access to the apex, impedes thorough cleaning and shaping of the canal thus may compromise the outcome of the Endodontic treatment<sup>7,8</sup>. In such cases, prognosis depends on condition of root canal (vital or non-vital), tooth (symptomatic and asymptomatic), with or without periapical pathology, the level of separation of instrument in the root canal<sup>7</sup>. Hence every attempt should be made to retrieve the broken instrument from the canal for a successful root canal treatment.

The major advantages of this method include minimal use of instruments, no advanced and complicated instrumentation technique required and feasible to all clinical set up. In spite of advantages this method is technically very sensitive due to various reasons including clinical skills, advancement of the broken instrument into the apical region or beyond the apex, breakage of the bypassed file into canal due to excessive pressure or uncontrolled instrumentation, apical transportation and perforation of the root canal<sup>9,10</sup>.

At times an instrument may be separated apical to the curvature of the canal. In such cases, a safe access to the site of separation may not be achieved. Then the retrieval of the separated instrument is not possible using this technique and surgery or extraction will be needed at times in presence of adverse signs and symptoms<sup>8</sup>.

## **CONCLUSION:**

The best antidote for the broken instrument is prevention. Adhering to proven concepts, integrating the best strategies and utilizing the safe technique during root canal procedure will virtually eliminate the broken instrument accidents. However, there are certain instances where the instrument will break inspite of the best techniques and technologies. In such circumstances if there is a clinical symptom and/or radiographic pathologies, surgical intervention of extraction of the tooth is the best treatment option.

## **REFERENCES:**

1. Mohan S, Gutru A, Guha C. Surgical Endodontics - An aid for the management of iatrogenesis. *JDSOR* 2012; 3:37-39
  2. Gandevivala A, Parekh B, Poplai G, Sayed A. Surgical Removal of Fractured Endodontic Instrument in the Periapex of Mandibular First Molar. *JIOH*. 2014; 6(4): 85-88.
  3. Walton R, Torabinajed M. Principles and practice of Endodontics. 3<sup>rd</sup>ed. W. B. Saunders Company: Philadelphia; 2002;370-80.
  4. Kunhappan S, Kunhappan N, Patil S, Agarwal P. Retrieval of separated instrument with instrument removal system. *JICDRO*. 2012; 4(1):21-24.
  5. Gutru A, Singhal A, Singhal P, Mohan Sumith. Retrieval of Separated Instrument in Mandibular Molar by Surgical Approach- A Case Report. *JDSOR*.2012;4:21-24.
  6. Cohen S, Burns RC. Pathways of Pulp. 8<sup>th</sup>ed. Elsevier: Philadelphia;2002;66-67
  7. Hulsmann M. Methods for removing metal obstruction from the root canal. *Endod Dent Traumatol*. 1993;9:223-37.
  8. Cohen SJ. Rips, Strips and Broken Tips: Handling the Endodontic Mishap Part I: The separated instrument. *Endodontics, Oralhealth*.2005;10-17.
  9. Pettiette MT, Conner, Trope M. Procedural errors with the use of nickel-titanium rotary instruments in undergraduate endodontics. *J Endod*2002;28:259.
  10. Shenoy A, Mandaya P, BollaNagesh, Vemuri S. A novel technique for removal of broken instrument from root canal in mandibular second molar. *IJDR*.2014;25(1):107-10.
-