

*International Journal of Scientific Research and Reviews*  
**Non - Syndromic Oligodontia : Report of Two Unique Rare Cases**

**P. Reghu, G.V.Murali Gopika Manoharan and M.Suresh Kumar<sup>\*</sup>**

Tamilnadu Government Dental College and Hospital, Chennai-600003 Tamilnadu, India.

**ABSTRACT:**

Agenesis of teeth is a common developmental anomaly which may involve single or multiple teeth. Oligodontia is commonly encountered in permanent dentition than deciduous. The etiology of oligodontia is proposed to be inherited or environmental. Most often oligodontia is associated with congenital syndrome. Isolated, nonsyndromic oligodontia is considered a rare entity. Oligodontia has serious implications for the patient as it results in altered facial feature, reduced masticatory function, and also has an impact on the psychological status of the patient. In this article, we report two rare cases of Non-syndromic Oligodontia. In one case congenital absence of 19 permanent teeth was noted and in another case congenital absence of 16 permanent teeth was noted.

**KEYWORDS:** Oligodontia, Hypodontia, Nonsyndromic, Permanent teeth

**\*Corresponding Author:**

**Dr. M. Suresh Kumar<sup>\*</sup>**

PG student, Department of Oral Medicine and Radiology

Tamilnadu Government Dental College and Hospital

Chennai - 600003, Tamilnadu

E Mail - [dr.kmsuresh@gmail.com](mailto:dr.kmsuresh@gmail.com)

Mob No. - 9894709507

## INTRODUCTION

Oligodontia refers to congenital absence of six or more teeth excluding third molar. Overall prevalence of oligodontia is about 0.14%. Females are more frequently affected than males with no difference in the distribution of missing teeth in maxilla and mandible. Cause of oligodontia is believed to be either inherited or environmental, associated with or without genetic syndrome. Non syndromic oligodontia usually presents as isolated familial trait, or as a sporadic finding. In this article we report two rare cases of non syndromic oligodontia with congenital absence of 19 permanent teeth in one case and 16 permanent teeth in the second case.

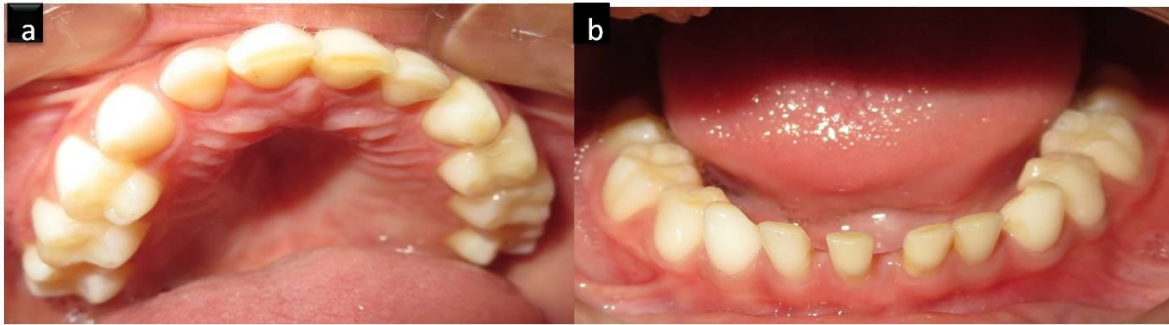
### CASE 1:

An 11-year-old male patient reported with a chief complaint of non formation of permanent teeth in both jaws. Family history of this patient revealed that he was born to parents of non consanguineous marriage. None of the family members were found to have similar features. On general examination patient was healthy, well nourished and well built. No significant abnormalities were noticed in skeleton, skin, nail, hair, eyes and ears. [Figure 1]

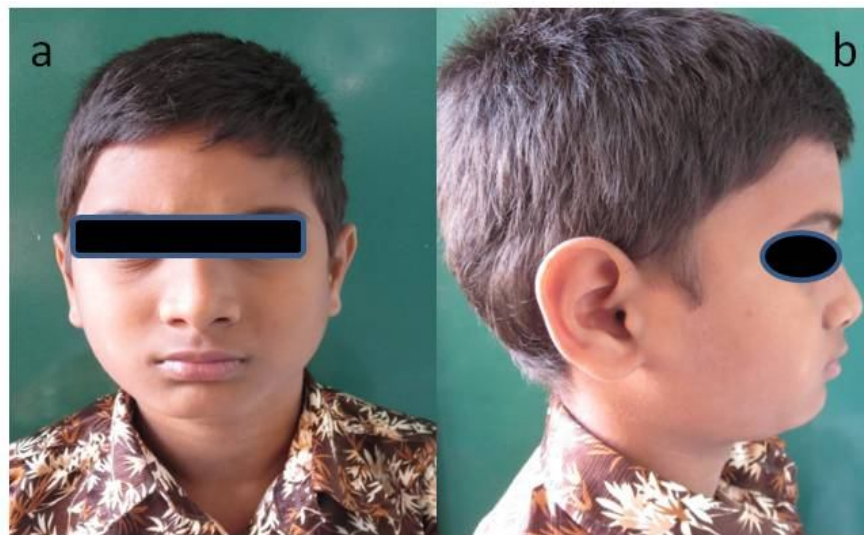

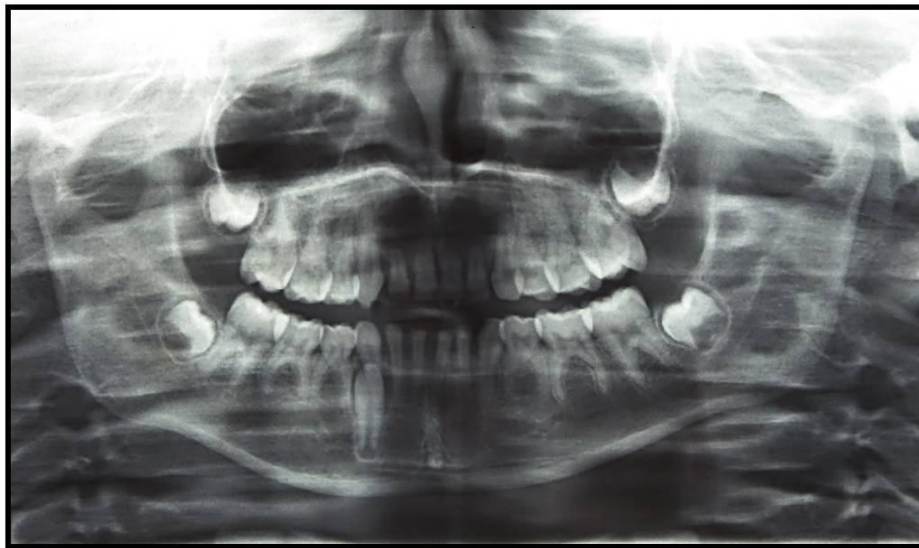
Figure 1: Extraoral frontal (a) and lateral (b) view of the patient

On intraoral examination all the deciduous teeth were present along with permanent first molar in all quadrants. All the teeth were of normal in size, shape and colour. [Figure 2]



**Figure 2: Intraoral view maxilla (a) and mandible (b) showing normal appearance of teeth with mixed dentition**

Orthopantomograph(OPG) of the patients revealed complete absence of all permanent successors except right lower canine with resorption of roots of deciduous upper and lower anterior teeth, developing tooth bud of permanent second molar.[Figure 3]

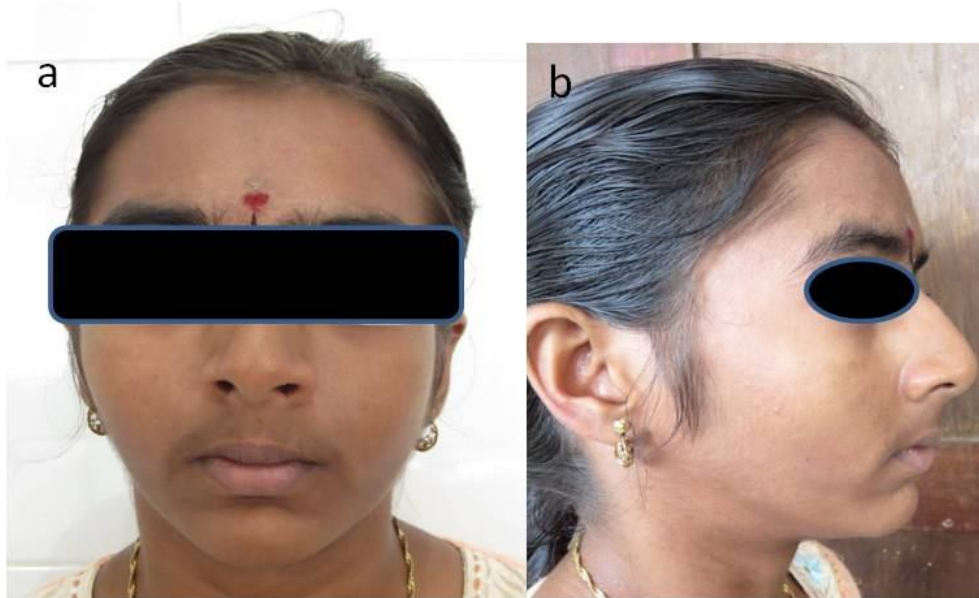

**Figure 3: OPG showing complete absence of permanent successor except 43.**

Hence overall 19 permanent teeth were missing excluding third molar. Physical and mental evaluation of the patient was carried out and there were no significant findings. Then the patient was referred for dermatological, neurological, ophthalmological and endocrinological assessments to rule out any congenital syndrome and the results were found to be non contributory. Based on the above characteristic findings, diagnosis of non syndromic oligodontia was given. The treatment plan considered for this patient was a multidisciplinary approach to resolve psychological and esthetic concerns.

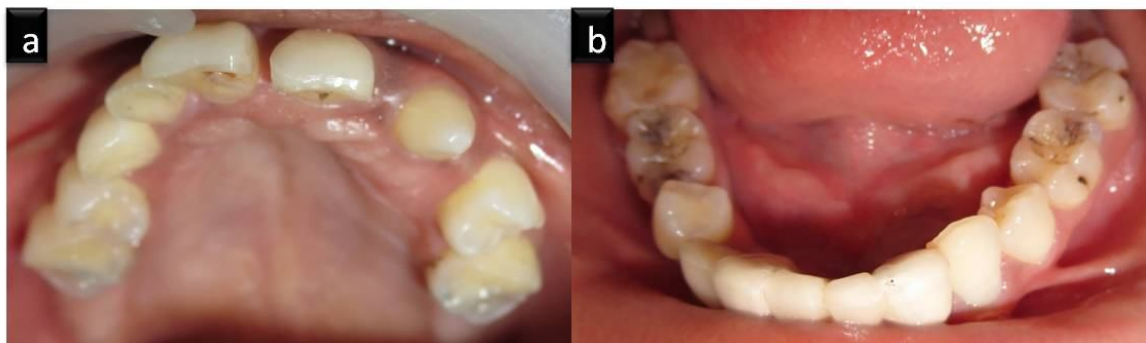
**CASE 2:**

A 16-year-old female patient diagnosed with megalocornea of both eyes was referred from Government General Eye Hospital to rule out oral focal sepsis. Past medical and family history were not contributory except for megalocornea. Patient had attained her puberty at the age of 14 and has a regular menstrual cycle. On general examination no significant abnormality were noticed except for megalocornea of both eyes for which surgery had been planned.[Figure 4]



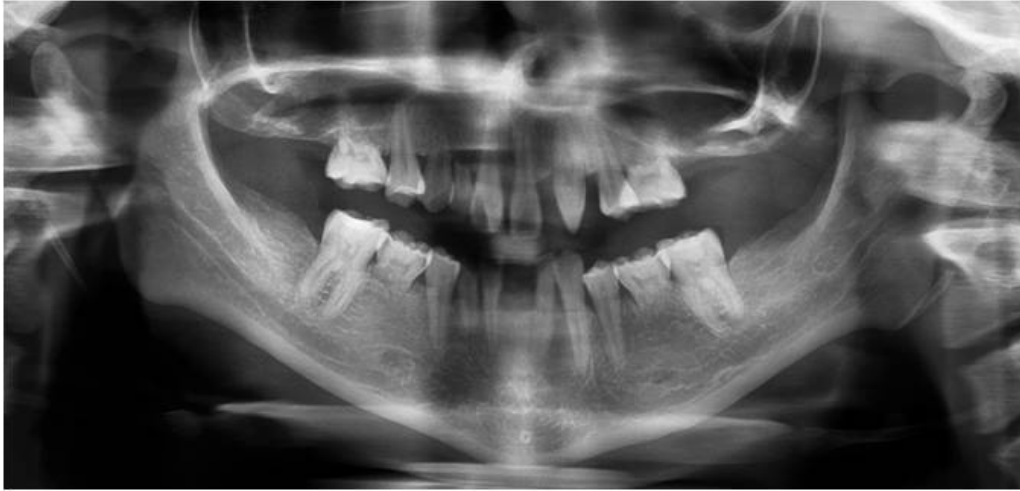**Figure 4: Extraoral frontal (a) and lateral (b) view of the second patient.**

Similar to the first case, no significant abnormalities were noted in skin, hair, nail, eye and skeleton. Intraoral examination revealed presence of multiple retained deciduous teeth 52,53,55,65,75,83,85 , permanent teeth 11,14,21,22,24,32,33,34,36,42,44,46. Size, shape and colour of the teeth were normal with unilateral cross bite on right side [Figure 5].



**Figure 5: Intraoral view of maxilla(a) and mandibular(b) arch . Note in lower arch fixed prosthesis done in relation to 32 and 42**

Orthopantomograph(OPG) showed no evidence of any developing permanent tooth bud or impacted teeth including second and third molar in both jaw with multiple retained deciduous teeth as examined clinically.[Figure 6]



**Figure 6: OPG showing congenital missing of 16 permanent teeth.**

Hence 16 permanent teeth were absent excluding third molars. This patient was also subjected to complete systemic evaluation including dermatological, neurological, ophthalmological, psychological and endocrinological assessments and no significant findings were reported. No significant correlation between megalocornea and oligodontia was observed. Considering above mentioned features and absence of significant abnormality on systemic examination, diagnosis of nonsyndromic oligodontia was given. Conservative management and prosthetic replacement was carried out to improve the psychological stress and esthetic appearance of the patient.

## **DISCUSSION:**

Among the various developmental disorders affecting the teeth, dental agenesis is the most common developmental anomaly, often presenting as a significant psychological and functional problem. Anodontia is the term given to complete absence of teeth both clinically and radiologically. Hypodontia refers to a condition with agenesis of one to five teeth and oligodontia is agenesis of six or more teeth, excluding the third molars.<sup>1</sup> In both the cases more than six teeth were missing, in first case 19 permanent teeth and in second case 16 permanent teeth were missing.

The prevalence of permanent tooth agenesis ranges between 1.6% and 9.6%, and the prevalence of deciduous tooth agenesis is lower, ranging between 0.5 % and 0.9 %. The prevalence of hypodontia in permanent dentition occurs in 2% - 10%, while in primary dentition it is rare and occurs in 0.1% - 0.9%. The prevalence for oligodontia is in ranges of 0.03% to 0.07%.<sup>2</sup> According to Muller et al, girls have a higher rate of congenitally missing permanent teeth than boys.<sup>3</sup>

Both environmental and genetic factors can cause failure of tooth development but in majority of the cases, oligodontia is genetically determined, although this does not exclude factors such as radiotherapy, medications, infectious diseases, trauma, endocrine and intrauterine disorders.<sup>4</sup> Many studies have shown the heritability of congenitally missing teeth. In most of the cases multiple genetic and environmental factors are acting together whereas genetic factors may be dominant or recessive. It is also reported that several genes which, when defective, cause congenitally missing teeth. Mutations in EDA, AXIN2, MSX1, PAX9, WNT10A, EDAR, EDARADD, NEMO and KRT 17 are known to associate with non-syndromic oligodontia.<sup>5,6</sup> Mutations of MSX-1 and PAX-9 genes have been associated with agenesis of teeth. Mutations in different genes may cause different types of oligodontia i.e. different sets of teeth are missing. However in our both cases genetic study was not carried out as both patients were not willing for genetic analysis.

Oligodontia is classified as isolated or nonsyndromic and syndromic type based on presence or absence of systemic involvement. Syndromic and nonsyndromic form of oligodontia can be differentiated by conducting thorough physical examination of hair, nails, sweat glands, eyes and skin for any congenital disorders. Oligodontia can occur in association with various genetic syndromes, such as Ectodermal Dysplasia, Incontinentia Pigmenti, Down syndrome, Rieger syndrome, Wolf-Hirschhorn syndrome, Van der Woude syndrome, Ectrodactyly- Ectodermal Dysplasia-Clefting syndrome, Cleft Lip Palate Ectodermal Dysplasia syndrome, Oral Facial Digital syndrome type I, Witkop Tooth-Nail syndrome, Fried syndrome, Hair- Nail- Skin- Teeth dysplasias. After complete physical, systemic and radiological evaluation, any kind of syndrome was not associated with both the cases reported in this literature.<sup>7,8</sup> Hence final diagnosis of nonsyndromic oligodontia was justified in both the cases.

Patient suffering from oligodontia are mainly affected with significant psychological, functional and esthetic problems. Dental treatment can vary depending on the severity of the disease and generally

requires a multidisciplinary approach involving the cooperation of orthodontist, prosthodontist and occasionally oral surgeon and endodontist.<sup>9</sup> Before treating a case of oligodontia several factors have to be taken in to considerations especially age of the patient, severity of oligodontia, severity of malocclusion and expectation of patient towards treatment. Orthodontic therapy is frequently required for proper positioning of the teeth prior to prosthetic replacement. Prosthetic rehabilitation with single tooth implant, removable or fixed partial prostheses and over dentures will help in improving the functional and esthetic outcomes.<sup>10</sup> Hence these cases should be evaluated carefully with emphasis on early diagnosis and treatment planning for better outcome and satisfaction of patient in all needs.

## **CONCLUSION:**

Consequences of missing teeth have lot of implications. Functional problems like mastication and speech and altered facial appearance can cause psychological distress to the patient limiting the quality of life. Hence Oligodontia cases require a multidisciplinary approach and should be evaluated carefully for the presence or absence of any syndromes and managed appropriately. Prosthetic and orthodontic therapy is often necessary for managing young oligodontia patients. Considering the implications of Oligodontia, early diagnosis and prompt treatment is necessary to prevent functional and esthetic problems in the future.

## **REFERENCES:**

1. Mahadevi B Hosur, RS Puranik, Shrinivas S Vanaki. Oligodontia: A Case Report and Review of Literature. *World Journal of Dentistry*. July-September 2011; 2(3): 259-262.
2. Zarrinnia K, Bassiouny MA. Combined aplasia of maxillary first molars and lateral incisors: a case report and management. *J Clin Pediatr Dent* 2003; 27: 127–132
3. Dhanrajani PJ. Hypodontia: etiology, clinical features and management. *Quintessence Int*. 2002; 33: 294–302.
4. Gupta D, Kamal M, Sharma H, Gupta S. Idiopathic nonsyndromic oligodontia in permanent dentition: A Case Report. *Indian J Dent Sci*. 2012; 4: 67–69
5. Biedziak B. Aetiology and occurrence of tooth agenesis: Review of the literature. *Dent Med Probl*. 2004; 41: 531–535.
6. Singwai Wong, Haochen Liu, Baojing Bai et al. Novel missense mutations in the AXIN2 gene associated with non-syndromic oligodontia. *Archives of oral biology*. 2014; 59(3): 349-353.

7. Ghazafaruddin M, Mishra G, Haseebuddin S, Mishra A. Oligodontia of Permanent Teeth: A rare case report. *Indian J Stomatol.* 2011; 2: 285-287.
8. Suda N, Ogawa T, Kojima T, Saito C, Moriyama K. Non-syndromic oligodontia with a Novel Mutation of PAX9. *J Dent Res.* 2011; 90: 382-386.
9. Creton MA, Cune MS, Verhoeven W. Patterns of missing teeth in a population of oligodontia patients. *Int J Prosthodont.* 2007; 20: 409-413.
10. Worsaae N, Jensen BN, Holm B, Holsko J. Treatment of severe hypodontia-oligodontia: An interdisciplinary concept. *Int J Oral Maxillofac Surg.* 2007;36:473-480