

## *International Journal of Scientific Research and Reviews*

### **Need of the Hour : Early and Rapid Diagnosis of Black Fungus (Mucormycosis) Maiming the Covid Patients in India!!!**

**Ujwala M.<sup>1</sup>, \*Shweta M.<sup>2</sup>, Navdeep K.<sup>2</sup>, Haripriya K.<sup>3</sup>, Dr.Srivalli S.<sup>4</sup>**

<sup>1</sup>Department of Pathology, MGM's Medical College and Hospital, Navi Mumbai. MH, India

<sup>2</sup>Department of Pathology, MGM's Medical College and Hospital, Navi Mumbai. MH, India

<sup>3</sup>Department of Microbiology, MGM's Medical College and Hospital, Navi Mumbai. MH, India

<sup>4</sup>Oral and maxillofacial surgery, MGM's Medical College and Hospital, Navi Mumbai. MH, India

#### **ABSTRACT:**

Mucormycosis is a very aggressive invasive fungal disease. It is a fungal emergency that affects a variety of patient groups. The disease, previously termed zygomycosis, is caused by mucoralean fungi, which have collectively also been called Mucormycetes.

Two cases a 55 year old male patient and 50 year old female patient whowere previously treated for covid infection two months back came to MGM hospital with the complaints of headache, facial swelling, oral ulceration and difficulty in breathing which did not resolve on medication. Patients were further investigated for the same and a strong clinical suspicion of mucormycosis was made keeping in mind the post-covid status and use of steroid for treating the same. Now as mucormycosis is a clinical emergency, rapid diagnosis of the same was necessitated and scrapings of the ulcerated oral lesions and oral wash was taken and subjected to KOH mount and rapid cytological stains.

Oral cytology is often a good choice for identification of infective agents; being noninvasive therefore easily acceptable by patients, quick, inexpensive, simple, accurate and requiring minimum paraphernalia. Results are dependable; causative organisms of most of the lesions are frequently diagnosed—only in few cases, advanced ancillary techniques are required for final diagnosis.

**KEYWORDS:** Mucormycosis, Black fungus, Mucorales, Periodic acid Schiff (PAS), Gommori's Methanamine Silver (GMS), Oral Scrapings, Oral Wash.

#### **\*Corresponding author:**

**Dr. Shweta Munot**

Post-graduate student, Department of Pathology,

MGM's Medical College and Hospital, Navi Mumbai. MH, India

E-mail: [shwetamunot1994@gmail.com](mailto:shwetamunot1994@gmail.com)

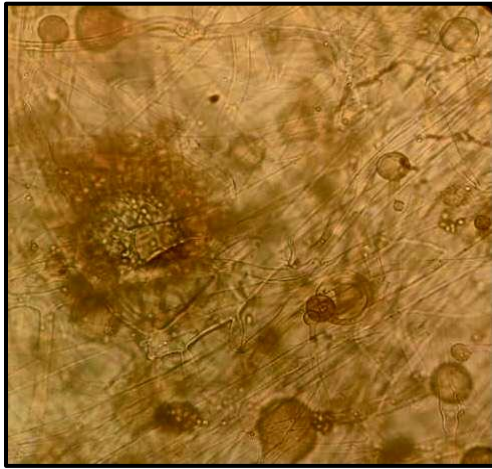
## **INTRODUCTION**

Mucormycosis is an extremely aggressive, life threatening fungal infection which is prone to invasion of the bone and soft tissue<sup>1, 2</sup>. It is a medical emergency now slowly taking a toll on people's life and taking the form of national emergency which has made a great impact on various patient groups both physically and emotionally<sup>1, 2</sup>. The entity, labelled previously as zygomycosis, is a result of infection by a mucoralean fungi one of which is Mucor<sup>1</sup>. As, in several instances, even in the patients with immune - compromised states, it presents clinically as a mild infection, thus being a challenge to the clinicians diagnostically and therapeutically. In such immuno-suppressed cases, rapid and early diagnosis with appropriate treatment becomes of utmost importance to prevent the morbidity and mortality caused by this infection<sup>2, 3</sup>. Lung injury caused because of affection of the patient by for Covid-19 is observed to be reduced by use of steroids, which also helps to combat the damage caused by cytokine storm which is induced by body's own immune system to destroy the covid-19 virus<sup>4</sup>. But conversely, steroid also appear to markedly reduce body's immunity so that it becomes easy for the opportunistic infection to set in and it also increases the body's blood glucose concentration in patients suffering from diabetes mellitus as well as non-diabetics affected by the dreadful corona virus. It is stated to be nightmare amidst this pandemic which has rendered human race helpless<sup>4</sup>. Zygomycosis may present clinically as mildly symptomatic to vivid clinical symptoms like obstruction of the nasal cavity, bloody discharge from nose, ulcerations in the oral cavity, excruciating facial pain or head ache, facial swelling or inflammation leading to cellulitis, visual problems with simultaneous proptosis, paralysis of the face due to affection of facial nerve in some cases<sup>5, 6</sup>. In its later course, the disease progression leads to involvement of cranial vault leading to loss of vision, seizures and eventually death<sup>5, 6</sup>.

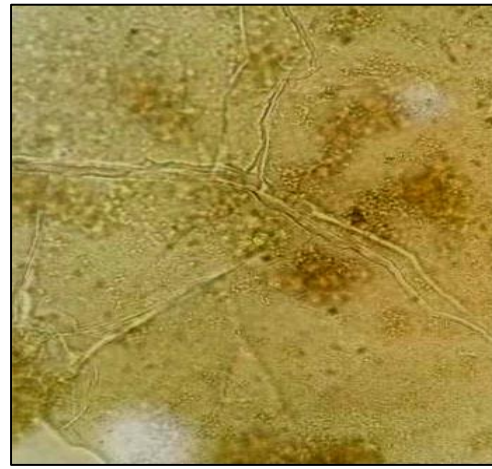
## **CASE HISTORY**

Two cases, a 55 year old male patient and 50 year old female patient who were previously diagnosed and treated for covid-19 infection two months back came to MGM hospital with the complaints of headache, facial swelling, oral ulceration and difficulty in breathing which did not resolve on medication. Patients were further investigated for the same and a strong clinical suspicion of mucormycosis was made keeping in mind the post-covid status and use of steroids for treating the same. Now as mucormycosis is a clinical emergency, rapid diagnosis of the same was necessitated and scrapings of the ulcerated oral lesions and oral wash was taken and subjected to KOH mount, rapid cytological stains and microbiological culture.

Potassium Hydroxide (KOH) mount was made on the bed-side of the patient and was observed under a light microscope after twenty minutes; both the cases showed presence of broad, hyaline aseptate hyphae with irregular branching suggestive of Zygomycetes.



**Figure 1**



**Figure 2**

Figure 1 & 2: KOH mount showing broad fungal hyphae of mucor in the patient's sample.

Slides were made from the oral scrapings of the patients and were air dried and subjected to Rapid Hematoxylin and Eosin (H and E) stain, and fungal stains such as Periodic Acid Schiff (PAS) Stain and Gomori's Methanamine Silver (GMS) stain. On light microscopy, H & E stained smears showed squamous cells along with neutrophilic infiltration and presence of multiple ribbon-like broad based, aseptate hyphae with branching at right angles and some irregularly branched suggestive of Mucor.

Light microscopic examination of PAS stained smears showed broad based, aseptate magenta coloured fungal hyphae with irregular branching and some showing branching at right angles, while GMS stained smears showed ribbon like black coloured broad based, aseptate hyphae with branching at right angles.

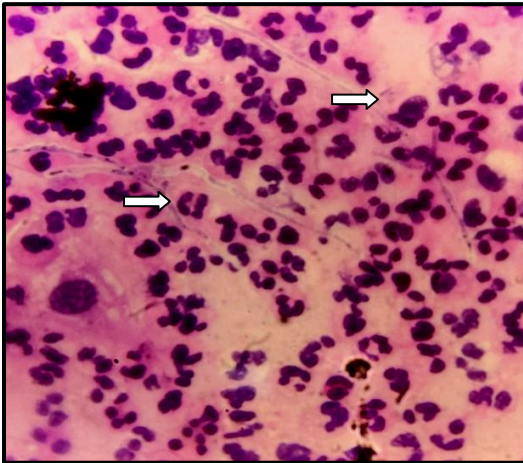


Figure 3

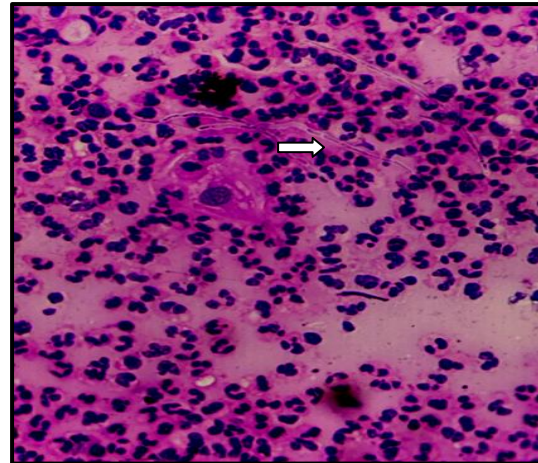


Figure 4

Fig. 3 & 4: Hematoxylin and Eosin stained smears from oral scrapings reveal fungal hyphae which are aseptate and showing branching at right angles and few showing irregular branching.




Figure 5

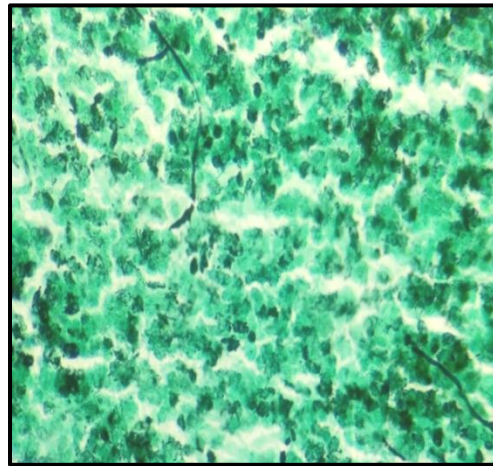


Figure 6

Fig. 5 and 6: Gomori Methanamine Silver stained smears studied reveal ribbon like fungal hyphae showing irregular branching suggestive of Mucor.

Oral wash of these patients was subjected to culture on Sabourard Dextrose Agar (SDA) as a confirmatory test for cytological diagnosis and white coloured fungal colonies of Mucor were identified which were then confirmed on examination by staining with Lactophenol Cotton Blue Stain.




Figure 7

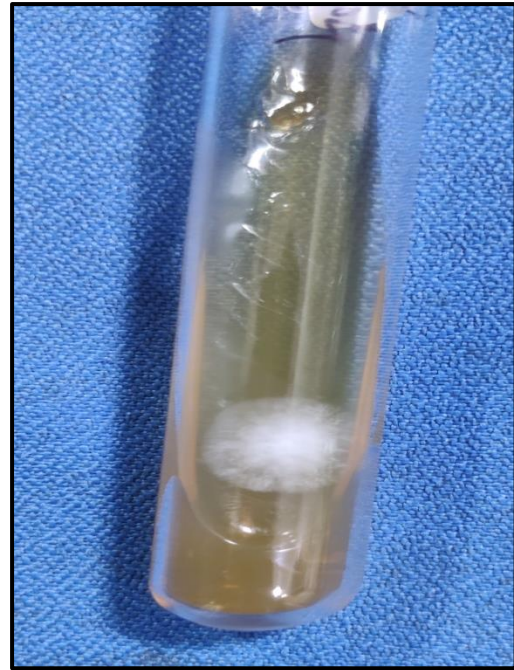

Figure 8

Fig. 7 and 8: Reveal Mucor colonies on Sabourard Dextrose Agar which was confirmed by microscopic examination of the same using Lactophenol Cotton Blue Stain.

## DISCUSSION

The clinical manifestations and radio-diagnostic features of the life threatening infection caused by the dreaded black fungus that is mucor shows a wide clinical variation and are not specific and a conclusive diagnosis of the same requires a direct observation and identification of the of the distinct fungal hyphae or observation of these hyphae from recovery of fungus culture of these organisms from the site of infection <sup>7</sup>. Collection of the samples for direct wet mount examination under light microscope, cytological or histo-pathological examination can be done directly from the visible wounds by scrapping, under the guidance of radiological tools like ultra-sonography guided percutaneous aspiration using a needle or by ultra-sonography or cyto-tomography guided biopsies of lesions <sup>7</sup>. Although histo - pathological examination is specific and reliable in establishing the diagnosis of mucormycosis in almost all the cases in which peculiar and very characteristic fungal hyphae are seen; but obtaining a biopsy from the deep tissues is difficult in untrained hands and is labour intensive and it also poses a great risk in patients with low platelet counts or coagulation defect leading to tremendous bleeding post procedure <sup>7</sup>. Mucormycosis being a life threatening infection showing high mortality, early diagnosis as soon as a clinical suspicion is made is the need of the hour and cyto-pathological examination using rapid H & E stain and special fungal stains aids

in the same along with the routine microbiological stains like Lactophenol Cotton Blue. Also the cherry on the cake for these cytological examination being that the samples obtained are by non-invasive procedures and do not require a well trained medical professional for the sample collection. Also on histo-pathological examination, the identification and interpretation of these organisms is difficult and may also be missed by a well trained and experienced pathologist whereas the sample of oral wash or saline wash from the affected site which are used for culture of the fungal organism is easy to obtain and culture is a gold standard test. In case of occulo-cerebral and rhino-occulo-cerebral mucormycosis, immuno-histochemical examination using different stains, Fluorescent In Situ Hybridization (FISH) or Polymerase Chain Reaction (PCR) are helpful for the diagnosis of mucormycosis<sup>7</sup>.

Once a conclusive diagnosis is obtained, therapies leading to immune-suppression are stalled if patients clinical condition allows for the same, and Liposomal Amphotericin-B treatment is initiated. Amphotericin-B is an anti-fungal effective against mucormycosis, but is very expensive and is not available easily due to production shortage in this covid era pertaining to increasing cases of mucormycosis. Clinical outcome and prognosis of these cases depends on the course underlying disease<sup>2</sup>.

## **CONCLUSION**

Due to varied clinical symptoms, most of the patients seek clinical advice later in the course of disease when they are starting to have a difficulty in vision and only treatment helpful is removal of the eye to stop the infection from reaching the brain<sup>4</sup>. These situations all the more increase the need for early, rapid and reliable diagnosis of this condition which can be obtained on cytopathological examination aiding the micobiological stains, using non-invasive methods of sample collection. One crude way to stop the spread of the fungal infection is to make sure that Covid-19 patients - both during and after the treatment for the same are followed clinically up on a regular basis along with stringent used of steroids during the treatment as prevention is always better and superior to cure<sup>4</sup>.

## **CONFLICTS OF INTEREST**

None.

## REFERENCES

1. A. Cornely<sup>1</sup>, S. Arikan-Akdagli, E. Dannaoui<sup>3</sup>, A. H. et al. ESCMID and ECMM joint clinical guidelines for the diagnosis and management of mucormycosis 2013 O.
  2. Vandana Raghunath, K Hanna Rose Priyanka, C Geetha Kiran, R Manasa Deepthi Mucormycosis – Can the diagnosis be challenging at times??
  3. Maureen M Roden<sup>1</sup>, Theoklis E Zaoutis, Wendy L Buchanan, Tena A Knudsen, Tatyana A Sarkisova, Robert L Schaufele. Epidemiology and outcome of zygomycosis: a review of 929 reported cases.
  4. Mucormycosis: The 'black fungus' maiming Covid patients in India Soutik Biswas Reddy SG, Kumar KK, Sekhar CP, Reddy RB. Oral mucormycosis: Need for early diagnosis!! 2014.
  6. Spellberg B, Edwards J Jr, Ibrahim A. Novel perspectives on mucormycosis: Pathophysiology, presentation, and management. Clin Microbiol Rev 2005; 18:556-69.
  7. *Clinical Infectious Diseases*, Volume 54, Issue suppl\_1, February 2012, Pages S55–S60, Published: 01 February 2012.
-