

## *International Journal of Scientific Research and Reviews*

### **Clinico-Hematological Profile in Visceral Leishmaniasis: a Study in Non-Endemic Region**

**Bhavneet Kour<sup>1</sup>, Suby Singh<sup>1\*</sup> and Pankaj Singh<sup>2</sup>**

<sup>1</sup>Department of Pathology, Government Medical College Jammu (J&K), India;

<sup>2</sup>Department of <sup>2</sup>Medicine; Government Medical College Jammu (J&K), India;  
[bhavpankaj30@gmail.com](mailto:bhavpankaj30@gmail.com), [bhavneet23@gmail.com](mailto:bhavneet23@gmail.com), [meet.suby@gmail.com](mailto:meet.suby@gmail.com)

#### **ABSTRACT**

Visceral Leishmaniasis (VL) is a parasitic disease caused by *Leishmania donovani* (LD). Leishmaniasis is considered to be disease of lowland as climate and geographical factors play an important role in the distribution of vector, parasite and reservoir. The present study was conducted to study the various clinical and hematological features associated with leishmaniasis in this non endemic region. This was a hospital-based retrospective cross-sectional study conducted in the Department of Pathology, Government Medical College Jammu for a period of 5 years. It included 31 patients of Visceral Leishmaniasis, who were diagnosed by demonstration of LD bodies on Bone marrow aspiration slides.

Out of the total 31 cases, 8 cases (26%) were suspected clinically by the physicians; while 23 cases (74%) had no clinical suspicion of Visceral Leishmaniasis. Fever and splenomegaly were the most common clinical findings found in almost all the cases followed by pallor and hepatomegaly. Lymphocytosis(100%) was the common hematological finding seen in all the patients. In bone marrow aspirate, LD bodies were present both extra cellular and intra cellular.

Leishmaniasis has emerged as an important parasitic infection in the non-endemic Himalayan and sub Himalayan region of India. Information, education and communication (IEC) can be the accurate method to make people of this area aware about this disease and majors for prevention.

**KEYWORDS:** Visceral Leishmaniasis, fever, hepatomegaly, clinical

#### **\*Corresponding Author:**

**Dr. Suby Singh**

Lecturer; Department of Pathology,

Government Medical College Jammu (J&K), India Contact No.- 7006867641

Email id: [meet.suby@gmail.com](mailto:meet.suby@gmail.com)

## **INTRODUCTION**

Visceral Leishmaniasis (VL) is a parasitic disease caused by *Leishmania donovani* (LD) with *Phlebotomus* sand fly being the vector of the disease. It results from the infection of macrophages in the reticulo-endothelial system associated with immune-inflammatory response.<sup>1</sup> Three forms of Leishmaniasis are known- visceral leishmaniasis (VL), Cutaneous leishmaniasis (CL) and mucocutaneous leishmaniasis (MCL). VL is the severest form of Leishmaniasis and if not treated, it is often fatal.<sup>2</sup>

Visceral leishmaniasis has an incidence of 0.2 to 0.4 million cases worldwide, causing 20,000-40,000 deaths annually.<sup>3</sup> It is mainly distributed in East Africa, South Asia, South America, and Mediterranean Region, with an approximately 50,000 to 90,000 new cases annually. More than 90% of VL cases were reported in Brazil, Ethiopia, India, Kenya, Somalia, South Sudan, and Sudan.<sup>4</sup>

Altogether India, Nepal and Bangladesh harbour an estimated 67% of global visceral leishmaniasis with an estimated 200 million people at risk. Only India contributes more than 50% of visceral leishmaniasis in states of Bihar, West Bengal, UP and Jharkhand, only Bihar contributes 90% cases from India.<sup>5</sup>

Leishmaniasis is considered to be disease of lowland as climate and geographical factors play an important role in the distribution of vector, parasite and reservoir.<sup>6,7</sup> However, recently few studies have reported leishmaniasis at higher altitude of Himalayan and sub Himalayan region of India.<sup>8,9,10</sup> LD bodies, the amastigote forms of the parasite which are demonstrated in the bone marrow are associated with various morphological changes which may give clue to the diagnosis of the infection.<sup>8</sup>

VL causes varied hematological abnormalities like anemia, leucopenia and thrombocytopenia. Normocytic normochromic anemia is a common feature of VL with Hb level of 7-10g/ dl. VL causes anemia due to multiple factors; Sequestration and destruction of red blood cells (RBC) in enlarged spleen, opportunistic infection, chronic disease, certain nutritional deficiencies, immune mechanism and alterations in RBC membrane permeability have been identified.<sup>11</sup> The leucopenia in VL patients is mainly due to decrease in neutrophilic leukocytes. This is believed to be due to hypersplenism. Eosinophil number is reduced significantly, while the percentages of monocytes are increased. In the other hand, absolute number of lymphocytes is slightly decreased but, there is controversial issues among different authors about the absolute number of lymphocytes in VL.<sup>12</sup> Several studies have

reported pancytopenia in the late stages of VL.<sup>13,14</sup> The cause of pancytopenia is assumed to be due to sequestration of blood cells in the spleen.<sup>12</sup>

## **MATERIALS AND METHODS**

This was a hospital-based retrospective cross-sectional study conducted in the Department of Pathology, Government Medical College Jammu for a period of 5 years. It included 31 patients of Visceral Leishmaniasis, who were diagnosed by demonstration of LD bodies on Bone marrow aspiration slides. The demographic profile, residence, clinical features, and haematological values on complete blood picture and morphological findings on bone marrow aspiration of each patient were recorded. The presence or absence of lymph node enlargement irrespective of the site was noted.

## **RESULTS**

The study included a total of 31 cases of Visceral Leishmaniasis diagnosed on bone marrow aspirate smears over a period of 5 years. Out of these, 22 cases were found in males and 9 cases in females.

Out of the total 31 cases, 8 cases (26%) were suspected clinically by the physicians; while 23 cases (74%) had no clinical suspicion of Visceral Leishmaniasis.

Table 1 shows the clinical findings in cases showing LD bodies on bone marrow aspirate. It shows that fever and splenomegaly are the most common clinical findings found in almost all the cases followed by pallor and hepatomegaly.

Table 2 shows the hematological findings of the patients. Lymphocytosis was the common finding seen in all the patients. Anaemia and pancytopenia were also seen in most of the patients. Majority of the patients had peripheral film showing microcytic hypochromic blood picture.

Table 3 shows the abnormal bone marrow findings of the patients. It was also seen that LD bodies were present both extra cellular and intra cellular.

**Table 1: Clinical presentation in cases showing LD bodies on BM aspirate**

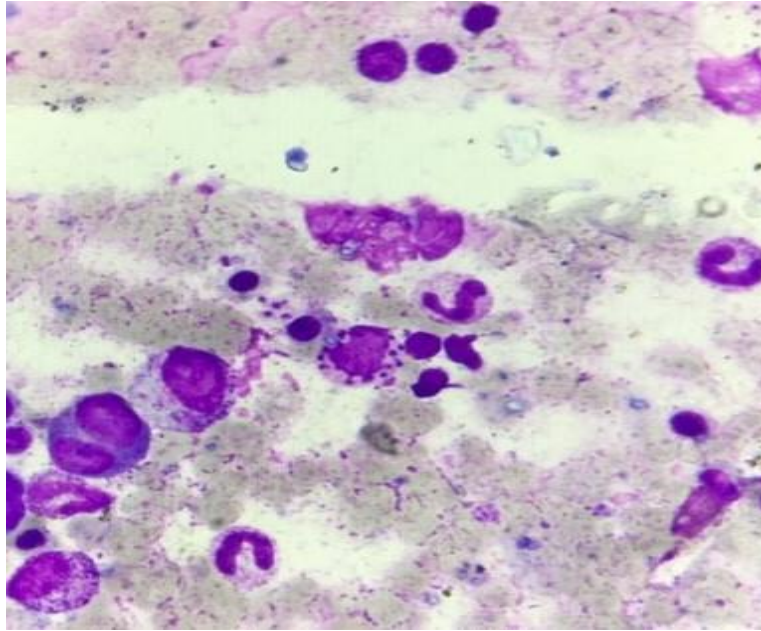
Clinical presentation	No. of cases	Percentage (%)
Fever	31	100
Pallor	29	93.5
Splenomegaly	31	100
Hepatomegaly	24	77.4
Loss of weight/appetite	21	67.7
Lymphadenopathy	9	29.0
Jaundice	3	9.7
Bleeding	3	9.7

**Table 2: Hematological findings on peripheral blood film**

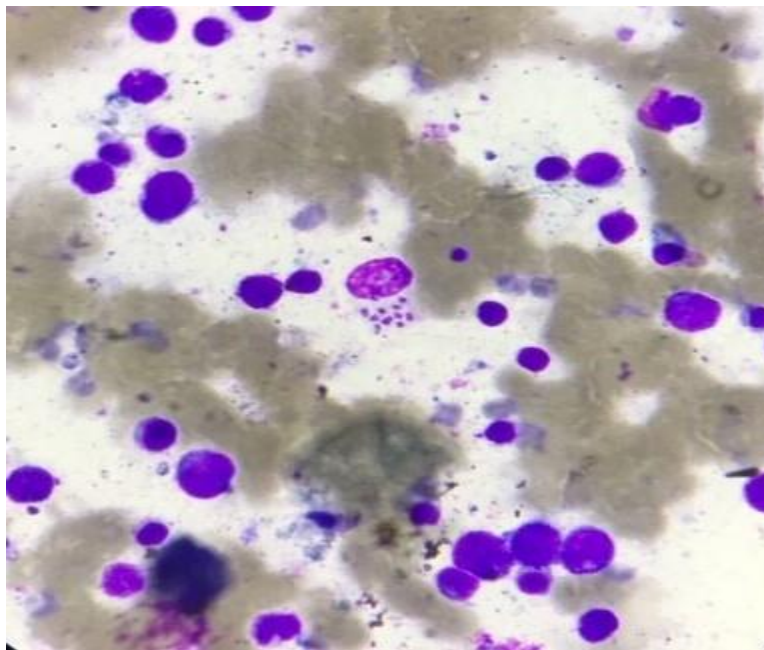
Peripheral blood film	No. of cases	Percentage
Anaemia	29	93.5
Pancytopenia	24	77.4
Leukopenia	20	64.5
Lymphocytosis	31	100
Thrombocytopenia	28	90.3
Monocytosis	15	48.4

**Table 3: Bone marrow findings on bone marrow aspirate**

Bone marrow findings	No. of cases	Percentage
Dyserythropoiesis	12	38.7
Dysmyelopoiesis	8	25.8
Prominent histiocytes	16	51.6
Prominent plasma cells	5	16.1
<b>Distribution of LD Bodies</b>		
Intracellular only	5	16.1
Extracellular only	15	48.4
Mixed	11	35.5
Hemophagocytosis	6	19.3



**Fig 1: Bone marrow aspirate showing intracellular LD Bodies (May Grunwald Giemsa, 100X)**



**Fig 2: Bone marrow aspirate showing extracellular LD Bodies (May Grunwald Giemsa, 100X)**

## **DISCUSSION**

India accounts for major burden of leishmaniasis worldwide with approximately 146,700-282,800 new cases being reported each year.<sup>13</sup> Though the disease is common in Bihar, West Bengal and other eastern states of India but a new focus of leishmaniasis is being observed in Himalayan and sub Himalayan regions of India in few recent studies.<sup>10,14</sup> This study is done to assess clinical and haematological changes associated with visceral leishmaniasis in this non endemic sub Himalayan region.

Our study also reported 31 cases of leishmaniasis over period of five years in our non-endemic sub-Himalayan region. The probable reason of this new focus may be associated with change in climatic condition, deforestation which may have resulted in change of vector breeding. In addition, increased migration of population from endemic areas due to heavy pilgrimage in this state may have also resulted in new cases of leishmaniasis in this hilly region.

In the present study fever and splenomegaly were the most common presentation and disease was unsuspected clinically in most of the cases. This could be because of its presence in non endemic region and the clinical features mimic with other common diseases like malaria, liver diseases or enteric fever which are commonly seen in this region. Dhingra et al reported pyrexia in 70% of cases in his study and splenomegaly in 100% cases.<sup>15</sup> Saurabh K et al showed pyrexia in 100% cases which is similar to our study.<sup>16</sup> Pallor was seen in 93.5% cases similar to other studies in which pallor was observed in 90-95% cases.<sup>16</sup> Lymphadenopathy was reported as an unusual characteristic feature in hilly areas in approximately 50% of cases whereas our study reported it in 29% cases.

Lymphocytosis (100%) Anaemia (93.5%) and thrombocytopenia (90.3%) were the most common haematological changes in this study. These findings are similar to the study done by Saurabh K et al.<sup>16</sup> On peripheral blood smear, RBC showed microcytic hypochromic blood picture in majority of cases similar to studies conducted by Hamid et al.<sup>17</sup> The predominance of microcytic, hypochromic blood picture could be due to undiagnosed long standing infection leading to anaemia of chronic diseases. Pancytopenia was also a common haematological abnormality (77.4%) similar to other studies.<sup>15,17</sup> Splenic sequestration of the blood cells is the main cause of Pancytopenia in Kala-azar. Suppression of the bone marrow due to high burden of the infection is relatively rare.<sup>16</sup>

On bone marrow examination plasma cells were seen in few cases of leishmaniasis in the present study. Another finding reported in the present study on bone marrow examination was presence of increased histiocytes and hemophagocytosis. The authors therefore suggest that vigilant search for LD bodies should be made even in unsuspected cases if histiocytosis and hemophagocytosis is present on bone marrow examination along with plasmacytosis. These findings are in concordance with the findings of Gupta et al<sup>14</sup> and Chandra et al.<sup>8</sup> Studies have also reported that LD bodies aggregates on bone marrow aspirate in form of rosettes, ring and strap shape which may be confused with fungal spores and therefore pathologists should be aware of such presentation to avoid misdiagnosis.<sup>8</sup> Interestingly, it has been previously reported that LD bodies may also be observed in non histiocytic cells like polymorphs, megakaryocytes and metamyelocyte.<sup>8</sup> However, none of the cases in our study showed presence of LD bodies in non histiocytic cells but the pathologist should be aware of this feature to avoid missing of diagnosis. Singh et al have concluded that visualization of LD body using microscopy is confirmatory diagnostic test for leishmaniasis but may not be possible in endemic areas. rK39 ELISA has emerged as an important laboratory test for diagnosis of leishmaniasis with high specificity and sensitivity.<sup>18</sup>

## **CONCLUSION**

Leishmaniasis has emerged as an important parasitic infection in the non-endemic Himalayan and sub Himalayan region of India. Fever, splenomegaly and pancytopenia are major clinical and peripheral blood examination findings associated with this disease. Hemophagocytosis and plasmacytosis on bone marrow examination should guide the pathologist for vigilant search of LD bodies in the marrow in order to avoid missing of diagnosis even in unsuspected cases and aid in early diagnosis and treatment of the disease. Information, education and communication (IEC) can be the accurate method to make people of this area aware about this disease and majors for prevention.

## **REFERENCES**

1. Herwaldt BL, Fauci AS, Braunwald E, Kasper DL, et al. Leishmaniasis in Harrison's Principles of Internal Medicine. 17<sup>th</sup> ed. McGraw Hill: New York, USA; 2008; 1296-1300.
2. Mauricio IL, Stothard JR, Miles MA. The strange case of Leishmania chagasi. Parasitol Today. 2000;16:188-90.
3. Faleiro RJ, Kumar R, Hafner LM, Engwerda CR. Immune Regulation during Chronic Visceral Leishmaniasis. PLoS Negl Trop Dis 2014;8(7).



4. Alvar J, Yactayo S, Bern C. “Leishmaniasis and poverty”. *Tren Parasitol* 2006;22(12):552–7.
5. Perry D, Dixon K, Garlapati R, et al. Visceral Leishmaniasis Prevalence and Associated Risk Factors in the Saran District of Bihar, India, from 2009 to July of 2011. *Am J Trop Med Hygiene*. 2013;88(4):778–84.
6. Bhunia GS, Kesari S, Jeyaram A, et al. Influence of topography on the endemicity of Kala-azar: a study based on remote sensing and geographical information system. *Geospat Health*. 2010;4(2):155-65.
7. Elnaiem DE, Schorscher J, Bendall A, et al. Risk mapping of visceral leishmaniasis: the role of local variation in rainfall and altitude on the presence and incidence of kala-azar in eastern Sudan. *Am J Trop Med Hyg*. 2003;68(1):10-7.
8. Chandra H, Chandra S, Kaushik RM. Visceral leishmaniasis with associated common, uncommon, and atypical morphological features on bone marrow aspirate cytology in nonendemic region. *J Trop Med*. 2013;2013.
9. Mahajan SK, Machhan P, Kanga A, et al. Kala-Azar at high altitude. *J Commun Dis*. 2004 Jun;36(2):117-20.
10. Kumar A, Vinita R, Thapliyal N, Saxena SR. Kala Azar-- a case series from non endemic area, Uttarakhand. *J Commun Dis*. 2012;44(3):145-9.
11. Varma N, Naseem S. Hematologic Changes in Visceral Leishmaniasis/ Kala Azar. *Indian J Hematol Blood Transfus* 2010;26(3):78-82.
12. Neki NS, Singh J. Hematological changes in Visceral Leishmaniasis. *Int J Curr Res Med Sci* 2017;3(6):36-40.
13. Alvar J, Vélez ID, Bern C, et al. Leishmaniasis worldwide and global estimates of its incidence. *PLoS One*. 2012;7(5):e35671.
14. Gupta A.K, Chandra H, Bharati V, et al. Clinico-hematological profile and morphological features on bone marrow aspirate in visceral leishmaniasis from non-endemic region. *Trop J Path Micro* 2019;5(6):408-412.
15. Dhingra KK, Gupta P, Saroha V, et al. Morphological findings in bone marrow biopsy and aspirate smears of visceral Kala azar: A review. *Indian J Pathol Microbiol*. 2010;53(1):96-100.



16. Saurabh K, Ranjan S, Prasad RR. Clinical and haematological parameters associated with patients of visceral leishmaniasis in a district of North Bihar. *Int J Community Med Public Health* 2017;4:1957-60.
17. Hamid GA, Gobah GA. Clinical and haematological manifestations of visceral leishmaniasis in Yemeni children. *Turk J Haematol.* 2009;26(1):25-8.
18. Singh OP, Sundar S. Developments in diagnosis of visceral leishmaniasis in the elimination era. *Journal of parasitology research.* 2015. DOI: [https://doi. Org / 10. 1155/2015/239469](https://doi.org/10.1155/2015/239469).