

## *International Journal of Scientific Research and Reviews*

### **Immunomodulatory Effects of *Terminalia Arjuna* in Fish Model**

**Jayavelu Vadivelu<sup>1\*</sup> and Gangadharan Malathi<sup>2</sup>**

<sup>1\*</sup> PG and Research Department of Biochemistry, Sri Akilandeswari Women's College,  
Wandiwash – 604 408, India.

<sup>2</sup> PG and Research Department of Biochemistry, Sri Akilandeswari Women's College,  
Wandiwash – 604 408, India.

---

#### **ABSTRACT**

The present study was undertaken to determine the possible beneficial effect of Arjunolic acid on liver and kidney injury caused by Cyclosporine A, a well-known immunosuppressant and the immunomodulatory effect of arjunolic acid in fish (*Carassius auratus*). Arjunolic acid was isolated from the bark of *Terminalia arjuna* using chromatographic method. Arjunolic acid has been proved to possess beneficial effect against various pathological states. It has cardio protective, nephroprotective and Immunomodulatory activity. Cyclosporine A was diluted in a lipid solution (olive oil) that was administered once a day at a daily dose of 20mg/kg body weight for 3 days. The control fish was maintained without induction. In fish model kidney is the hemopoietic system. Hence, the present study was focused in liver and kidney. Arjunolic acid extract (10 mg/ kg body weight) was administered to fish (*carassius auratus*) for 3 days along with Cyclosporine A. In the fish (*carassius auratus*) the lysosomal enzyme activity and histopathological studies of liver and kidney were carried out. Hence, in future Arjunolic acid extract serves as a promising Phytochemical that can be developed as an immunoadjuvant in the aqua culture and in pisci culture.

**KEY WORDS:** Cyclosporine A, Arjunolic acid, *Terminalia arjuna*, immunomodulatory

---

#### **\*Corresponding Author**

**Dr. J. Vadivelu**

PG & Research Department of Biochemistry

Sri Akilandeswari Women's College

Vandavasi – 632 317Tamilnadu, India.

Email: [vadivelu2015@gmail.com](mailto:vadivelu2015@gmail.com), Mobile No: 9597134736

## INTRODUCTION

Liver and kidney plays a important role in detoxification and excretion of many endogenous and exogenous compounds. Any impairment to its functions may lead to many implications on one's health. Management of liver diseases is still a challenge to the modern scientific community.<sup>1</sup> The beneficial effects of *Terminalia arjuna* bark powder and its extract were also established in liver and kidney diseases as a immunomodulators.<sup>2</sup> The immune system is defense system of the body that provides protection against foreign particles, which are disease causing microbes.<sup>3</sup> The bark of *Terminalia arjuna* is a deciduous tree of combretacea family, has been widely used for the treatment of various diseases.<sup>4</sup> Cyclosporine exposure on renal dysfunction after cardiac transplantation, two large studies demonstrated that no relationship between cyclosporine concentration and the decline in renal function measured as the slope of serum creatinine as a function of time or by serial GFR measurements.<sup>5</sup> And a case-control study showed that cyclosporine doses and trough levels in the 24 heart transplant patients,<sup>6</sup> who developed end-stage renal disease were not different from those of patients who maintained stable renal function.<sup>7</sup> Aquaculture is the fastest growing animal food sector producing with an average annual increase of 6.2% per year. Numerous studies have shown that fish treated with medicinal plants enhanced immune parameters,<sup>8,9</sup> for example fish (*carassius auratus*) fed with a immunosuppressive agent cyclosporine A for a period of 3 days .The medicinal plants have hepatoprotective properties, immunomodulatory effects and anti inflammatory activities.<sup>10</sup> Investigation was projected to determine toxicity profile of the bark extract of *Terminalia arjun* in experimental fishes. It was also investigated for their hematological, biochemical, and histopathological changes in liver and kidney tissues after the treatment.<sup>11</sup>

## MATERIALS AND METHODS

### *Plant Material*

*Terminalia Arjuna*, belonging to the family Combretaceae, holds a reputed position in both Ayurveda and Yunani systems of medicine. The bark of *Terminalia Arjuna* was obtained from local market and was authenticated. The experiments were conducted according to the ethical norms approved by ministry of social; Justice and empowerment, Government of India and institutional Animal Ethics Committee guidelines (IAEC No. Bio BWC. 009/2010).

### *Preparation of the Extract*

The extract of *Terminalia Arjuna*, extract containing Arjunolic acid was carried out by following the method.<sup>12,13</sup> Briefly, after collection the bark of *Terminalia Arjuna* was cut into small piece, dried and ground into power (1 kg) which was then extracted with petroleum ether (20 h) to

remove greasy non polar material. After removing the petroleum ether the crude material was subsequently extracted with diethyl ether (40 h). The crude material was filtered and evaporated then purified to column chromatography. The crude material was filtered off and the mother liquor was concentrated under reduce pressure to yield a yellowish white amorphous solid which showed two spots on thin layer of chromatography.

### ***Fish and Maintenance Condition***

A total of 24 fish were randomly distributed in 4 rectangular tank filled with 250 L of well water. Fish were fed twice a day based on their body weight. All the aquaria were aerated continuously and total 90% of the water was exchanged weekly thrice. Fishes were maintained under these conditions and acclimatized for one week. Then the fish was treated with cyclosporine A and arjunolic acid for 3 days. The tissues were used as an experimental animal for further studies.

### ***Cyclosporin A Induced Toxicity in Fish***

Cyclosporine A was diluted in a lipid solution (olive oil) that was administered once a day at a daily dose of 20mg/kg body weight. There was without induction of control fish.

## **EXPERIMENTAL DESIGN**

The experimental animals were grouped into 4 groups of six fishes each follows:

**GROUP I:** Control untreated fishes.

**GROUP II:** Cyclosporine A (20 mg/kg body weight) was administrated for a period of 3 days.

**GROUP III:** Cyclosporine A induced (20 mg/kg body weight) and treated with *Terminalia Arjuna* extract containing Arjunolic acid (10 mg/ kg body weight) for 3 days.

**GROUP IV:** Treated with *Terminalia Arjuna* extract containing Arjunolic acid (10 mg/ kg body weight) for 3 days.

## **HISTOPATHOLOGICAL STUDIES**

One animal from each of the treated groups showing maximum activity as indicated by improved biochemical parameters was used for this purpose. The animals were sacrificed and the abdomen was cut open to remove the liver and kidney. The liver and kidney was fixed in Bouin's solution (mixture of 75 mL of saturated picric acid, 25 mL of 40% formaldehyde and 5mL of glacial acetic acid) for 12 h and then embedded in paraffin using conventional methods<sup>14</sup>. They were then cut into 5  $\mu$  m thick sections and stained using haematoxylin-eosin dye and finally mounted in diphenylxylene. The sections were observed under a microscope for histopathological changes in liver architecture and their photomicrographs were taken.

## RESULT AND DISCUSSION

Recent years, Phytochemicals have been extensively investigated as a source of medicinal agents.<sup>15,16</sup> Thus it is anticipated that Phytochemicals with adequate antioxidant efficacy can be used for the treatment of various diseases. A great number of natural medicinal plants have been tested for their antioxidant activities and results have shown that the raw extracts were more effective. Thus medicinal plants are best potential source of natural antioxidants.<sup>17</sup>

There are now numerous studies suggesting that various forms of chemical and physical stress can damage or destabilize the lysosomal membrane, thereby leading to the leakage of lysosomal enzymes into the cytosol of the cell. In similar our present study indicates the Cyclosporine A induced fishes are also increase the activity of lysosomal enzymes in kidney of *carassius auratus* it leads to over activity of enzymes and leakage of lysosomes in cells this can be suppressed by the Arjunolic acid.

Cyclosporine A is one of the immunopressive agents in the management of solid organ transplantation.<sup>18</sup> Arjunolic acid extract of *Terminalia Arjuna* have been proved to possess therapeutic effects in many clinical studies. The previous study shows that the bark extract of *Terminalia Arjuna* has a definite immunomodulatory effect and also possess cardio protective, anti-inflammatory, antihepatotoxic and immunomodulatory property in mice.<sup>19</sup> Our present study is linked with the above report in fish model.

The present investigation revealed that administration of Cyclosporine A (20 mg/kg daily for 3 days) resulted in liver and kidney toxicity as evidenced by marked deterioration of renal function. Many researchers have reported the immunomodulatory and anti-inflammatory activity in *Terminalia Arjuna*.

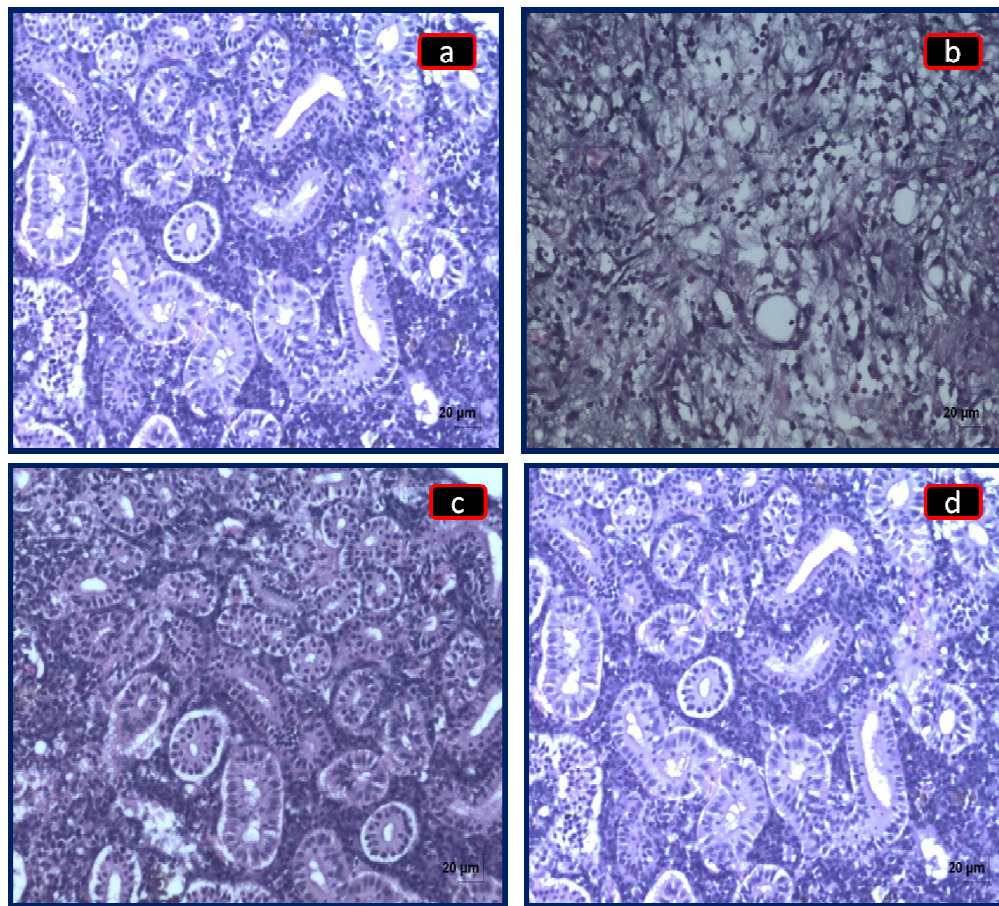
The present investigation revealed that administration of Cyclosporine A resulted in immunosuppressant activities, as evidenced by the activity of lysosomal enzymes like, acid phosphatase  $\beta$ -D-Galactosidase,  $\beta$ -D-Glucuronidase, N-acetylglucosaminidase and cathepsin D. This observation was correlated well with earlier observation that demonstrated significant changes including anti-inflammatory action and functional dearrangement in experimental animals following Cyclosporine A administration.<sup>20</sup> The treatment of fish (*Carassius auratus*) with arjunolic acid extract along with Cyclosporine A reduced the activity compared with Cyclosporine A treated and brought back to near normal. In the present study, Cyclosporine A treated fishes resulted in hepatotoxicity as evidenced by the marked decreased level of ALP, AST and ALT which has reported in previous studies. This observation was correlate with earlier observation which demonstrated significant changes in hepatic cells during Cyclosporine A administration. The

treatment of fish with arjunolic acid extract along with Cyclosporine A has brought back to near to normal. It shows arjunolic acid can protect the hepatic cells.

Previous study shows the goldfish *Carassius auratus* nephron, like that of the mammal, can regenerate the proximal tubule epithelium following toxic injury. The source of these cells appears to be primarily from the distal portions of the nephron. What signals these cells to synthesize DNA and to divide is unknown. Several theories have been proposed to explain proliferative responses in the kidney.<sup>21,22,23,24</sup> The nephrotoxic substance could have a direct effect on the cells, inducing them to divide. The toxicant may, however, indirectly stimulate the cells to divide by inducing the production or release of mitogens, or by removing an inhibitor of<sup>25</sup> division.

Histopathological studies also confirm that the treatment regimen of arjunolic acid in Cyclosporine A treated fish was able to alleviate the toxic effect of Cyclosporine A as evidenced by the regeneration of glomerulus. Hence, the present study indicates use of arjunolic acid aqua culture techniques to combat the stress related problem.

**Figure: 1 Histopathological Analysis Of Kidney In Control and Experimental Fish (*Carassius Auratus*)**



**Haematoxylin and eosin stained kidney section of 630 x:**

**Group-I:** Kidney from control (a) indicates the normal.

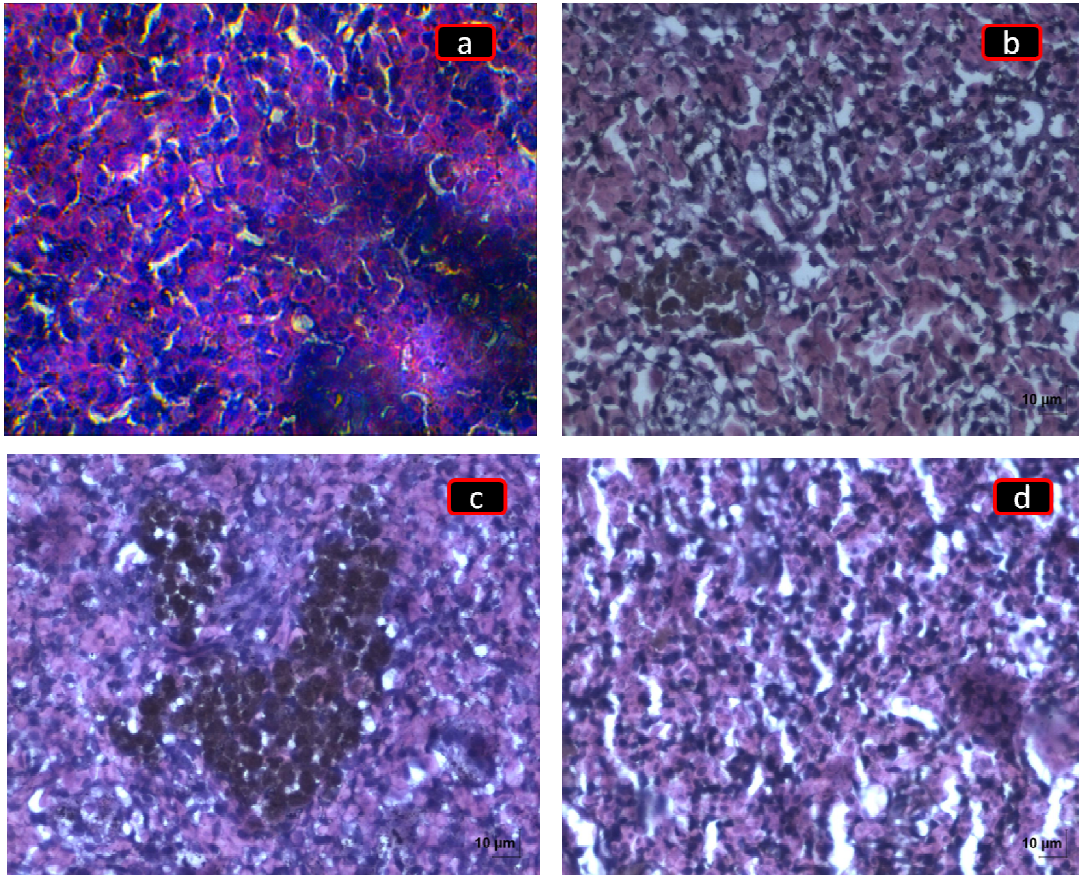


**Group-II:** Cyclosporine A treated. (b) Indicates the tubular epithelial degeneration, infiltration of heterophils, and congestion and accumulation of melanomacrophages.

**Group-III:** Cyclosporine A + Arjunolic acid treated. (c) Indicates the regeneration and swelling of tubular epithelium.

**Group-IV:** Arjunolic acid alone treated. (d) Indicates the regeneration of epithelium.

**Figure 2: Histopathological Analysis Of Liver In Control And Experimental Fish (*Carassius Auratus*)**



**Haematoxylin and eosin stained liver section of 630 x:**

**Group-I:** Liver control fishes revealed a normal.

**Group-II:** Cyclosporine A treated. Multiple foci of melanomacrophages are present.

**Group-III:** Cyclosporine A + Arjunolic acid treated. Multiple foci of melanomacrophages accumulation are present.

**Group-IV:** Arjunolic acid alone treated same in normal control.

## CONCLUSION

From this investigation it is evident that, the need of the hour is to explore the drugs which are effective on immune system. The synthetic immunostimulants has reported with adverse effects, hence, there is a need to develop herbal immunomodulators without adverse effect. The effect of arjunolic acid to nullify the toxic effect of Cyclosporine A and immunomodulatory effect were recognized in fish model.

## REFERENCES

1. J.Anbu Jeba Sunilson, M. Muthappan, AmitavaDas, R. Suraj, R. Varatharajan and P. Promwichit, “Hepatoprotective Activity of *Coccinia grandis* Leaves Against Carbon Tetrachloride Induced Hepatic Injury in Ratsk” , *International Journal of Pharmacology*, 2009; 5(3): 222-227.
2. Gauthaman K., Maulik M., Kumari R., Manchanda SC., Dunda AK., Maulik S.K., “Effect of chronic treatment with bark *Terminalia arjuna*: a study on the isolated ischeemic reperfusef rat heart”, *J. Ethnopharmacol*, 2001 ; 75 (2-3):197-201.
3. Nazish Jahana, Khalil-ur-Rahmanb, Sajjad-ur-Rahmanc and Fareeha Kousara “Immunomodulatory Potential of Gemmomodified Extract of *Terminalia arjuna*”,*IOSR Journal of Pharmacy and Biological Sciences*, 2017; 12(2): 18-22.
4. Gurvinder singh Anu T.Singh, Aji Abraham, Beena Bhat, Ashok Mukherjee, Ritu Verma, Shiv K. Agarwal, Shivesh jha, Rama Mukherjee, Anand C. Burman “Protective effects of *Terminalia arjuna* against Doxorubicin induced Cardiotoxicity”, *Journal of Ethanopharmacology*, 2008; 117: 123-129.
5. P. Vasanthi and C. S. Parameswari “Nephroprotective effect of arjunolic acid on cytosolic lipids and mitochondrial enzymes against cyclosporine induced renal complications in rats”, *International Journal of Pharmacological Research*, 2015; 11(5): 2277-3312.
6. Zietse R., Balk A.H., vd Dorpel M.A., Meeter K., Bos E., Weimar W., “Time course of the decline in renal function in Cyclosporine-treated heart transplant recipients” *Am. J. Nephrol.* 1994; 14: 1–5.
7. Björn Lindelöw, Claes-Håkan Bergh, Hans Herlitz, Finn Waagstein., “Predictors and evolution of renal function during 9 years following heart transplantation”, *J. Am. Soc Nephrol.* 2000; 11: 951–957.
8. Süheyla Karataş Düğenci Nazli & Arda Akın Candan, “Some medicinal plants as immunostimulant for fish”, *Journal of Ethno pharmacology* 2003; 88(1): 99-106.

9. Yuan B.Z., Jefferson A.M., Baldwin K.T., Thorgeirsson S.S., Popescu N.C., “ Reynolds S.H DLC-1 operates as a tumor suppressor gene in human non-small cell lung carcinomas”, *Oncogene*, 2004; 23:1405–1411.
10. Affy Mataphouet Emmanuel, Kouakou Koffi Roger, Douhoure Gnaore Toussaint, Kouakou Koffi. ”Acute and subacute toxicity of the aqueous extract of *Amaranthus viridis* (*Amaranthaceae*) leaves in rats”, *The Journal of Pharmacology* 2018; 7(4): 366-372.
11. Mohammad Daud Ali, Mohammad Arif Naseer, Mohammad Aamir Mirza<sup>2</sup>, Md. Sarfaraz Alam., ”Hematological, biochemical, and histopathological study of the plant extract of *Terminalia chebula* Reitz., *Aloe vera* Linn., and *Tamarindus indica* Linn. on animal model: A comparative study”, *National Journal of Physiology, Pharmacy and Pharmacology* 2019; 9(3): 268-275.
12. King. J., “The dehydrogenases or oxidoreuctases- lactate dehydrogenase. Practical clinical enzymology Van D (eds) ”,. Nostrand co ltd London, 1965; 83-93.
13. Braja G.Bag, Subhash R.Pramanik & Gopal C. Maity, “Arjunolic acid in molecular first sythesis and cation binding studies of a novel *Arjuna- 18- Crown-6*”, *Supramolecular chemistry*, 2005; 172(4): 297-302,.
14. Albert Edward Galigher and Eugene,N. Kozloff, “Essentials of Practical Micro Technique”, 2nd Edn., Lea and Febiger, New York, 1971.
15. Stanislaw Burda & Wieslaw Oleszek, “Antioxidant and antiradical activities of Flavonoids”, *J. Agric. Food Che* 2001; 49(6): 2774-2779.
16. Nidhi Tyagi, Ganesh N Sharma, Vikas Hooda., “Phytochechal and Pharmacological profile of *Lagenaria Siceraria*”. *International Research Journal of Pharmacy* 2012; 3(3): 1-3.
17. Damodar Shanbhag & Amit Khandagale., “Screening And Standardisation Of *Terminalia Arjuna* Used As Medicine In Homoeopathy Using HPTLC Method”, *International Journal of Analytical and Bioanalytical Chemistry*, 2011; 1(3): 57-60,.
18. Padi SS, Chopra K., “Salvage of cyclosporine A induced oxidative stress and renal dysfunction by carvedilol”, *Nephron* 2002; 92: 685-692.
19. Sumita Halder, Nidhi Bharal, Pramod K. Mediratta, Inderjeet Kaur and Krishna K Sharma, “Anti-inflammatory, immunomodulatory and antinociceptive activity”, *Indian Journal of Experimental Biology*, 2009 ;47: 577-583.
20. Peter Barany, Peter Stenvinkel, Astrid Ottoson- Seeberger , Anders Alvestrand , Janson Morrow , Jackson Roderts II & Abdulla K. Salahudeen, “Effects of 6 weeks of vitamin E administration on renal heamodynamic alterations following a single dose of neural in healthy volunteers”, *Nephrol. Dial. Transplant.* 2001; 16: 504-584.



21. F.E.Cuppige & E. Tate, "Repair of the nephron following injury with mercuric chlorid", *Am. J. Path.* 1967; 51(3): 405-429.
22. H. Cain, E. Egner & M. Redenbacker, "Increase of mitosis in the tubular epithelium following intrarenaldoses of various kidney homogenates and homogenate fractions in the rat" ,*Virchows Arch. (B Cell path.)* 1976; 22: 55-72,.
23. Herbertson BM., King AJ., Allen J., "Epithelial cell proliferation in the rat urinary system induced by parenteral injection of lead salts", *Br. J exp. Pathol.* 1987; 68(2): 167-177.
24. G.Andersson & E.Jennische, "IGF-I immunoreactivity is expressed by regenerating renal tubular cells after ischaemic injury in the rat", *Acta physiol. scand.* 1988; 132(4): 453-457.
25. Reimschuessel R., Bennett R.O., May E.B and Lipsky M.M., "Renal tubular cell regeneration, cell proliferation and chronic nephrotoxicity in the goldfish *Carassius auratus* following exposure to a singlsublethal dose of hexachlorobutadienl", *Dis. aquat. Org.* 1990; 8: 211-224.