

International Journal of Scientific Research and Reviews

Histopathological Changes of Syncytial knot in Normal and Pregnancy Induced Hypertension

Goswami Parth R.*, Shah .Shaila N., Gohil Mayuri

Department of pathology, Government medical college, Bhavnagar.

ABSTRACT

Placenta is the most important and vital organ of intrauterine life. Hypertension is one of the common complication met within pregnancy and contributes significantly to maternal and fetal morbidity and mortality. If the placenta is examined minutely it provides much insight into the prenatal health of the baby and the mother. This study is undertaken to assess the morphology of Syncytial knot in pregnancy induced hypertension and compare the same with that of normal pregnancy.

Fifty mothers with uncomplicated pregnancy and fifty mothers with pregnancy induced hypertension were selected randomly from in-patients of Obstetrics and Gynecology Department. Then syncytial knot formation number compared between two groups using chi square test.

Syncytial knot counts were found to be significantly higher in PIH group as compared to control group.

Pregnancy Induced Hypertension alters the placental histomorphology. The Syncytial knot number is high in PIH group that was statistically significant as compared to Normal. This will contribute to the better understanding, treatment and finally optimal management of the problem.

KEYWORDS: Placenta; Preeclampsia; Eclampsia; hypertension.

Corresponding author:

DR.Parth R. Goswami

102, Sangath flat, shilpinagar, kalanala, Bhavnagar.

Phone no. 9099097923

Email.. goswamiparth42@gmail.com

INTRODUCTION

Generally physicians are uncomfortable with the task of examining placenta, but according to benirschke placenta examination provide information much insight into prenatal life.¹ Syncytial knots are uncommon before 32 week of gestation.They increase in number after that period until at term where 10-30% of villi will have knots.In pregnancy induced hypertension(PIH) syncytial knots are excessive and seen in >30% of the villi.

They have been considered as an accumulation of apoptotic nuclei, a degenerative phenomenon as a response to trophoblastic ischemia or hypoxia and as incidental by product of the development of vasculo-syncytial membranes in the syncytiotrophoblast.²

Aladjem was of the opinion that, syncytial knots represent reactivation of the syncytiotrophoblast by examining the placenta under phase contrast microscopy.³

Syncytial knots are also reported to occur as a result of hypo perfusion of villi secondary to obliterative lesion of fetal stem arteries. Recent studies have demonstrated that reduced intra-placental oxygenation resulted in aggregated, web like arranged villous profiles with impressive syncytial knotting.²

According to Tenney's proposal syncytial knot is a degenerative nuclear and cytoplasmic modification.⁴ Wislocki and Dempsey found nuclear, cytoplasmic, and histochemical signs of premature aging in cases of PIH,an opinion shared by other investigators.^{5,6,7}

Various studies have supported positive relationship of the syncytial knots with pregnancy induced hypertension..Descriptions included: (1)The exuberant growth of the syncytiotrophoblast forming syncytial sprouts in contact with the blood of the intervillous space in placenta from eclamptic patients⁸ (2)Ectodermal hyperplasia⁹ (3)a finding of hypertrophy and hyperplasia of the syncytiotrophoblast and an increase of PAS positive material, these changes ascribed to a disturbance of the steroid metabolism¹⁰ (4)a proliferation ,with rejuvenation, of the cytotrophoblast¹¹ (5)a theory of hyperplacentosis¹² (6)an increase in syncytial knots¹

OBJECTIVES

1. To study the histomorphology of placenta regarding syncytial knots in normal and pregnancy induced hypertension.

2. To draw necessary conclusions from the study and make a comparative analysis of the results with those available in the literature.

MATERIALS AND METHODS

Fifty mothers with uncomplicated pregnancy and fifty mothers with pregnancy induced hypertension were selected randomly from in-patients of Obstetrics and Gynecology Department (Gopnath maternity), Sir Takhtasinhji General Hospital, Bhavnagar, Gujarat.

They were divided into two groups as Control group and PIH group.

Control Group: This group comprised of pregnant women with normal blood pressure, no proteinuria or edema.

PIH Group: This group comprised of pregnant women with blood pressure at or above 140/90 mm of Hg on at least two occasions, six or more hours apart after 20 weeks of present pregnancy together with or without proteinuria, edema, convulsions and coma.

The placenta were collected immediately following delivery and washed in tap water. The shape, fetal surface, placental membrane and umbilical cord insertion was determined. Then histologically syncytial knot formation compared between two group.

Data were statistically analyzed using Chi square test. This was done using EPI INFO 7 software. In all the tests 'p' value less than 0.05 was taken to be statistically significant and a value less than 0.01 was taken as highly significant.

Syncytial knots were seen as focal aggregates of syncytial nuclei forming a multinucleated protrusion from the villous surface. The number of villi with syncytial knots were recorded and the result expressed as a percentage of the total. A true syncytial knot was only accepted as such if it was visible on low power magnification and the actual counts were carried out using the high power magnification.

Based on the aggregation around the terminal villi (TV), the SKs in the present study were grouped into type 1, 2a, 2b, and 3.¹³

In type 1, SKs were found to accumulate to any one side of the TV leaving back the rest of the circumference of villi allowing free perfusion through VSM.

In type 2a, SKs accumulate almost half of the circumference of the TV and only a minimum area related to VSM was left for perfusion. In type 2B, the SKs were collected in two or three small groups surrounding the TV.

In type 3, three fourth of the circumference of TV was covered with SKs thus having the less chances of perfusion.

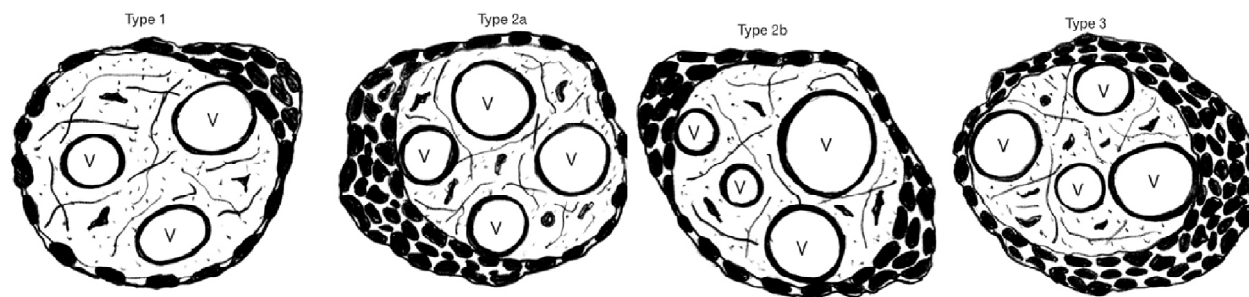


Figure 1 : Different types of syncytial knot

RESULTS

A total of 100 placentas were studied, out of which 50 (50%) placentas were from normal term mothers (BP <140/80mm Hg) which formed the control group and 50(50%) placentas were from mothers with PIH (BP > 140/80mm Hg) who formed the PIH Group. Of these 40 cases were of preeclampsia, 7 cases of gestational hypertension and 3 cases of eclampsia.

In both control and PIH groups mothers, majority belong to the age group between 20-30 years. Of the 50 controls 20 (40%) were primigravida and 30 (60%) were multigravida and out of 50 PIH cases 35 (70%) were primigravida and 15 (30%) were multigravida. This shows that in the present study PIH was more common in primigravida.

Mean systolic blood pressure in control group was 122 and PIH group was 152 mm of Hg. The mean diastolic blood pressure in control group was 80 and PIH group was 98 mm of Hg.

Table 1. Syncytial knot formation in control and PIH group

Microscopic lesions	No.of placenta showing microscopic changes		Percentage of placenta showing microscopic changes	
	Control group N=50	PIH group N=50	Control group N=50	PIH group N=50
Syncytial knot formation in >30% of villi	03	37	06%	74%
Type 1 syncytial knot	01	06	02%	12%
Type 2 syncytial knot	02	24	04%	48%
Type 3 syncytial knot	00	07	00%	14%

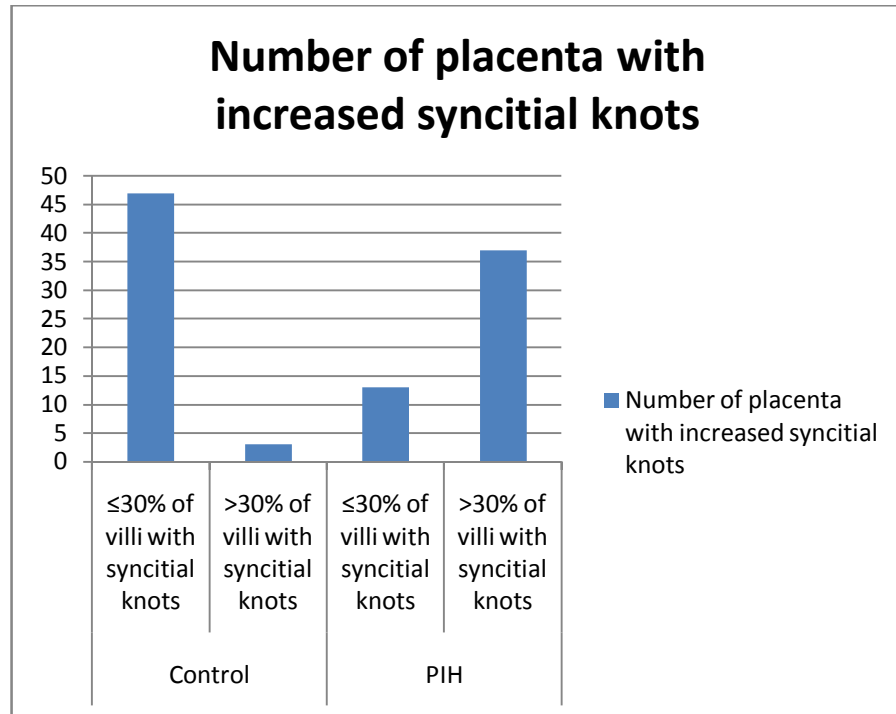


Figure 2: Syncytial knot formation control and PIH group. (Bar diagram presentation)

DISCUSSION

Incidence of eclampsia (3 out of 50) was low due to good obstetric care. The incidence of preeclampsia landing in eclampsia was less similar to that reported by Menon.¹⁴

Jain et al and Manjunatha et al compared the number of PIH placentas delivered with **parity** and found that 45.91 % of control mothers and 54.09 % of PIH mothers were primigravidas. This is in accordance with the previous studies.^{15,16}

Table 2. Comparison of syncytial knot in present study(PIH) with that of studies by Narasimha¹⁷ et al and Navbir¹⁸ et al.

Microscopic Lesions	Percentage of placenta showing the microscopic lesions (%)					
	Present study (2013-2014)		Narasimha et al (2011)		Navbir et al (2012)	
	Control (n=50)	PIH (n=50)	Control (n=37)	PIH (n=63)	Control (n=30)	PIH (n=30)
Syncytial knots >30% of villi	06	74	45	90.47	6.67	66.67

Syncytial knot counts were found to be significantly higher in PIH group as compared to controls and in cases of eclampsia of the PIH group. The findings of the present study correlated well with other studies.^{17,18}

Table 3: Comparison of syncytial knot in present study with that of studies by Narasimha et al¹⁷ and Navbir et al.¹⁸

Microscopic lesions	Percentage of eclamptic placenta showing themicroscopic lesions (%)			
	Present study (n=3) (2013-2014)	Kurdukar et al (2007) (n=10)	Narasimha et al (2011) (n=9)	Navbir et al (2012) (n=6)
Syncytial knots >30 % Of villi	100	100	100	100

As the severity of the disease increased like in eclampsia, the microscopic lesions where seen in increased number of villi (100 %) in the present study, these findings concur with other studies.^{17,18,19}

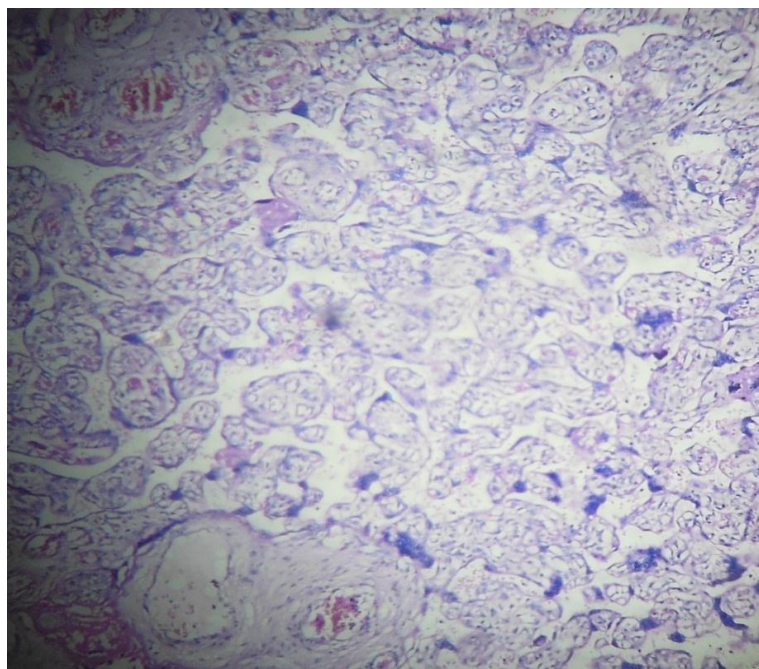


Figure 3. Figure showing excessive syncytial knots...

CONCLUSION

- Quantitative determination of placental changes is essential in study of placenta as normal pregnancies can also show similar placental changes due to ageing.
- Hypertensive disorders in pregnancy influence the morphology of placenta especially excessive syncytial knot which adversely affects the perinatal outcome.

-In pregnancy induced hypertension excessive syncytial knot more as compared to normal pregnancy.

REFERENCES

1. Benirschke K, Kaufmann P. Pathology of the human placenta. 2nd ed. New York: Springer Verlag; 1990.
Kaufman P, Castellucci M, Development and anatomy of the placentae. In: Fox H, Well M editors, Haines and Taylor Obstetrical and Gynecological Pathology, 5th ed., London: Churchill Livingstone; 2003: 1233-1268.
2. Alajdem S, Morphology of the human placental villi and the fetal outcome, J Obstet Gynecol BR, 1968; 75:1237-1244.
4. Bremer JL, The interrelations of the mesonephros, kidney and placenta in different classes of animals, Am J of Anat 1916; 19: 179-210.
5. Baloch AH, Memon SF, Ansari AK, Comparison of placentae from hypertension associated pregnancies and normal pregnancies, JLUMHS 2012; 11(1):3-6.
6. Raghunath G, Vijayalakshmi, Shenoy V, A study on the morphology & morphometry of human placenta & its clinical relevance in a population in Tamilnadu, J Clin Diagnost Research 2011 Apr; 5(2): 282-286.
7. Kurdukar MD, Deshpande NM, Shete SS, Zawar MP, Placenta in PIH, Indian J Pathol Microbiol 2007; 50 (3): 493-497.
8. Jain K, Kavi V, Raghuvver CV, Sinha R, Placental pathology in pregnancy induced hypertension with or without intrauterine growth retardation, Indian J Pathol Microbiol 2007; 50 (3): 553-557.
9. Shah RK, Jagiwala KS, Vyas PK, Placental morphology and fetal growth in normal and abnormal pregnancies, J Obstet Gynecol India 1984; 1089-1092.
10. Manjunatha HK, Kishanprasad HL, Ramaswamy AS, Aravinda P, Muddegowda PH, Lingegowda JB et al, Study of histomorphological changes in placenta in pregnancy induced hypertension, Int J Cur Sci Res 2012; 2(1):255-258.
11. Udainia A, Jain ML. Morphological study of placenta in pregnancy induced hypertension with its clinical relevance. J Anat Soc India 2001; 50(1): 24-27.
12. Majumdar S, Dasgupta H, Bhattacharya K, Bhattacharya A, A study of placenta in normal and hypertensive pregnancies, J Anat Soc India 2005; 54(2): 1-9.
13. Sankar KD, Bhanu SP, Kiran S, Ramakrishna BA, Shanthi V. Vasculosyncytial membrane in relation to syncytial knots complicates the placenta in preeclampsia: a histomorphometrical study.

Anat Cell Biol 2012; 45: 86-91

14. DuttaDC, The placenta, In: DuttaD.C., editor-Text book of obstetrics including Perinatology and contraception, 3rd ed., Calcutta, India: New Central Book Agency; 1992: 28-40.
15. Boyd JD, Hamilton WJ, The human placenta, Cambridge, England: W. Heffer And Sons; 1970: 114-189.
16. Fox H, Pathology of placenta, 2nd ed., Philadelphia: W.B. Saunders co.ltd.; 1997
17. Mudaliar, Menon, Hypertensive disorders of pregnancy, In: Clinical Obstetrics, Chennai: Orient Longman LTD; 1997: 133-154.
18. Hypertensive disorders of pregnancy, Report of a WHO study group, Geneva: World Health Organization; 1987
19. Kurdukar MD, Deshpande NM, Shete SS, Zawar MP, Placenta in PIH, Indian J Pathol Microbiol 2007; 50 (3): 493-497.