

International Journal of Scientific Research and Reviews

Secondary Hemophagocytic Lymphohistiocytosis in Dengue Patients - Retrospective Study in a Tertiary Care Hospital

Hoogar M.B., *Shweta Munot, Ruchi K., Disha V. and Shilpi

Department of Pathology, MGM's Medical College and Hospital, Navi Mumbai. India

E-mail: shwetamunot1994@gmail.com

ABSTRACT:

Hemophagocytic Lymphohistiocytosis (HLH), also known as Haemophagocytic syndrome, is relatively rare but not uncommon, in certain geographic endemic or viral infections such as Dengue fever. They are potentially fatal anomalous functional and putatively structural conditions, particularly, when occurring in young patients with inherited pattern of the disease but overactive histiocytes and lymphocytes that commonly appears in infancy, although it has been seen in all age groups.

The aims and objectives of the study are as follows:

1. To study and establish the prevalence of Haemophagocytic Lymphohistiocytosis (HLH) in Dengue patients; 2. To study and determine the prevalence of Haemophagocytic Lymphohistiocytosis (HLH) in other cases of infectious and non-infectious conditions including neoplastic conditions. 3. To study various parameters as recommended in 2009 criteria for diagnosis of Haemophagocytic Lymphohistiocytosis (HLH) and to determine which of the criterion/criteria is/are consistently found in most of the patients with Haemophagocytic Lymphohistiocytosis (HLH).

The present study, a retrospective one during six month period from July 2019 to January 2020, includes review of clinical records of all diagnosed cases of Dengue admitted in a tertiary care teaching hospital of MGM's Medical College in Navi Mumbai region of Maharashtra state of India.

In the present study, a total of seven cases of Haemophagocytic Lymphohistiocytosis or haemophagocytic syndrome were observed in a study of 294 cases of Dengue. All the cases were diagnosed based on modified 2009 criteria of diagnosis. Overall, the prevalence rate of HLH is found to be 2.3 per cent.

***Corresponding author:**

Dr. Shweta Munot

Associate Professor, HOD, Department of Pathology,

MGM's Medical College and Hospital, Navi Mumbai. India

E-mail: shwetamunot1994@gmail.com

INTRODUCTION

Hemophagocytic Lymphohistiocytosis (HLH) is a quite uncommon and often fatal disease of normal but overactive histiocytes and lymphocytes that commonly appear in infancy, although it has been seen in all age groups. It is often under recognized for its low contribution to its high mortality and morbidity^{1,2}. It is an immune hyperactivation syndrome characterized by clinical signs and symptoms of severe uncontrolled inflammatory pathology involving histiocytes³.

Although HLH is now being increasingly detected in clinical practice due to improved understanding on the part of physicians, pathologists and microbiologists; still much work by way of research remains to be done to raise awareness, explore treatment options and improve outcome of this complex clinical condition³. It may develop subsequent to a number of recognized genetic mutations or in association with infections, malignancy, auto-inflammatory or metabolic conditions⁴. There are two main forms of Haemophagocytic Lymphohistiocytosis: primary or familial HLH and secondary (acquired) HLH. Secondary HLH can be associated with infections, autoimmune disorders or malignancies. Despite attempts to differentiate between primary and secondary forms of HLH, it has ostensibly become difficult to do so in view of their similar clinical features³⁻⁵. Distinctions between primary (genetically determined) and secondary (acquired) forms of HLH have become increasingly blurred together as new genetic causes are identified⁵. The predominant clinical findings of Hemophagocytic Lymphohistiocytosis (HLH) are fever (often hectic and persistent), cytopenias, hepatitis and hepatosplenomegaly, decreased activity of cytotoxic T lymphocytes and natural killer(NK) cells as well as widespread accumulation of lymphocytes and macrophages that carry out hemophagocytosis, particularly of lymphocytes^{3,5}. HLH also forms the basis of differential diagnosis of number of diseases commonly found in children, such as autoimmune diseases, primary immunodeficiencies, malignancies, and microbial infections such as viral, bacterial and Fungal, and is more commonly seen in tropical countries^{3,6,7}. The most common infection-associated with HLH is caused by Epstein-Barr virus (EBV-HLH)^{3,6,7}.

The global incidence of Dengue infection, of late, has highly increased and the number of cases worldwide has been estimated at 390 million annually⁷. This mosquito-borne virus infection occasionally develops into a potentially lethal clinical state called severe dengue (SD)⁷. Despite prompt and appropriate fluid and electrolyte as also specific clinical management, dengue mortality is considerable and some patients with SD develop HLH (dengue virus-associated HLH [dengue-HLH])^{11, 12}. Thus,

dengue-HLH is a subset of SD, and of secondary HLH (sHLH). Significantly, sHLH is potentially fatal but treatable condition provided appropriate and timely clinical management is initiated^{7,8,9}.

Macrophage activation syndrome (MAS) is a severe and potentially life-threatening complication of many systemic diseases that show a particular association with Systemic Juvenile Idiopathic Arthritis (sJIA)¹⁰. MAS belongs to the spectrum of Hemophagocytic Lymphohistiocytoses (HLH), a group of both genetic and acquired conditions characterized by a hyperinflammatory mechanism driven by the uncontrolled secretion of pro-inflammatory cytokines due to the proliferation of activated lymphocytes and histiocytes^{10, 11}. This systemic, widespread inflammation can result in a wide range of clinical manifestations and laboratory abnormalities, including, but not limited to, hyperferritinemia, pancytopenia, liver and coagulation dysfunction and central nervous system involvement¹⁰.

MATERIAL AND METHODS

The present study, a retrospective study, consists includes analysis of all cases of Dengue fever with positive dengue NS1 antigen, and/or immunoglobulin (Ig) M (IgM) enzyme-linked immunosorbent assay (ELISA) and/or IgG ELISA admitted to the Mahatma Gandhi Medical College and Hospital, Navi-Mumbai during the period from July 2019 to January 2020. Cases without various diagnostic parameters for Dengue or diagnostic criteria (2009) for HLH were excluded from the study. This study was approved by the Institutional Ethics and Research Committee. Being a retrospective study, it includes review of clinical, pathological, microbiological and biochemical records of all diagnosed cases of Dengue admitted in MGM's Medical college and hospital, Navi Mumbai. A total of 294 Dengue cases were diagnosed in the said period and were retrospectively evaluated for Hemphagocytic Lymphohistiocytosis as defined by modified HLH-2009 diagnostic criteria.(Table 1).

As a diagnostic measure, the following laboratory parameters of Dengue cases were studied: hemoglobin, hematocrit, leukocyte count, absolute neutrophil count, platelet count, Aspartate transaminase (AST), Alanine transaminase (ALT), lactate dehydrogenase (LDH), serum ferritin, triglycerides, fibrinogen, and serum creatinine. Clinical parameters included for diagnosis of HLH were fever, splenomegaly, and hepatomegaly, and hemophagocytosis if evaluated.

TABLE 1: Modified HLH 2009 criteria

<i>2009 Criteria for diagnosis of HLH</i>
<i>At least THREE of the following:</i>
<ol style="list-style-type: none"> 1. Fever 2. Splenomegaly 3. Cytopenia (Any two of : Hb < 9gm%, Platelets < 1 lakh, TLC < 1000) 4. Hepatitis
<i>At least ONE of the following:</i>
<ol style="list-style-type: none"> 1. Ferritin elevation 2. Increased CD 25 (IL 2) 3. Hemophagocytosis on tissue biopsy 4. Abnormal/ Decreased NK cell activity.
<i>Other supportive Features</i>
<ol style="list-style-type: none"> 1. Hypertriglyceridemia 2. Hyperfibrinogenemia 3. Decreased sodium levels

RESULTS

In the present study, data from a total of 294 cases of Dengue, confirmed by NS1 antigen positivity, were analysed and as per the diagnostic criteria for HLH, seven cases of HLH were diagnosed. It was found that the prevalence rate of HLH was 2.3 per cent.

Of the total 294 cases of Dengue, 208 were males (71.1%) and 86 were females (28.9%). Of the 208 male Dengue patients, three were confirmed to be having HLH, which accounted for 1.4 per cent of all HLH cases. Out of 86 female Dengue patients, four were confirmed cases of HLH that accounted for 4.6 per cent of all HLH cases.

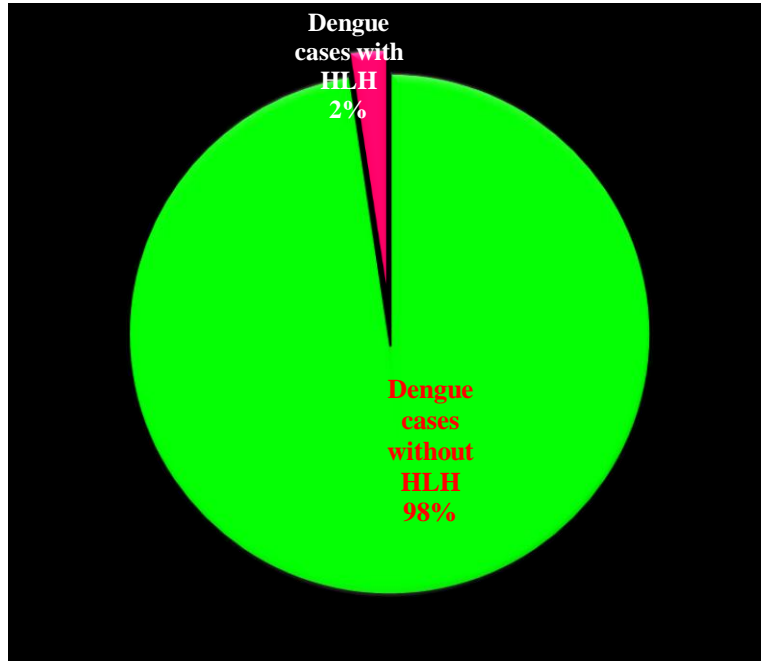


Figure 1 : Incidence of HLH in Dengue positive cases in current study

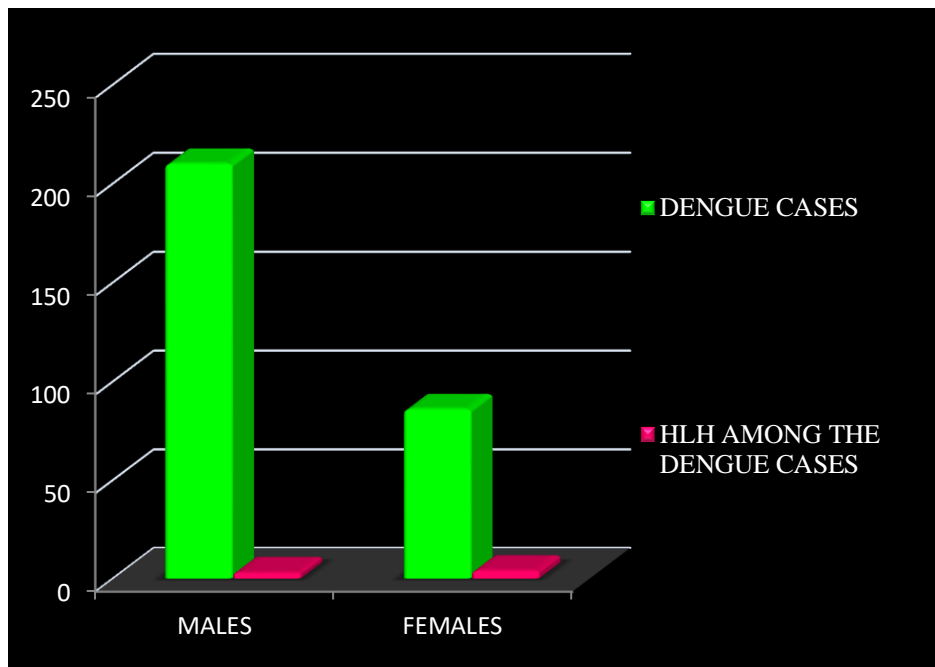


Figure 2 : Sex-wise distribution of HLH cases in the present study.

Of a total seven patients of HLH, 03 (42.8%) were between age-group of 0-10 years, 02 (28.5%) were between the age-group of 11-20 years and one case (14.2%) each occurred in individuals between age-groups of 21-30 and 31-40 years, respectively.(Table 2)

Table 02: Age-wise distribution of HLH cases post Dengue.

Age groups (years)	Total Dengue Cases	HLH cases from these dengue cases	Percentage
0-10	18	03	42.8
11-20	66	02	28.5
21-30	113	01	14.2
31-40	46	01	14.2
41-50	27	00	-
51-60	17	00	-
61-70	07	00	-
Total	297	07	

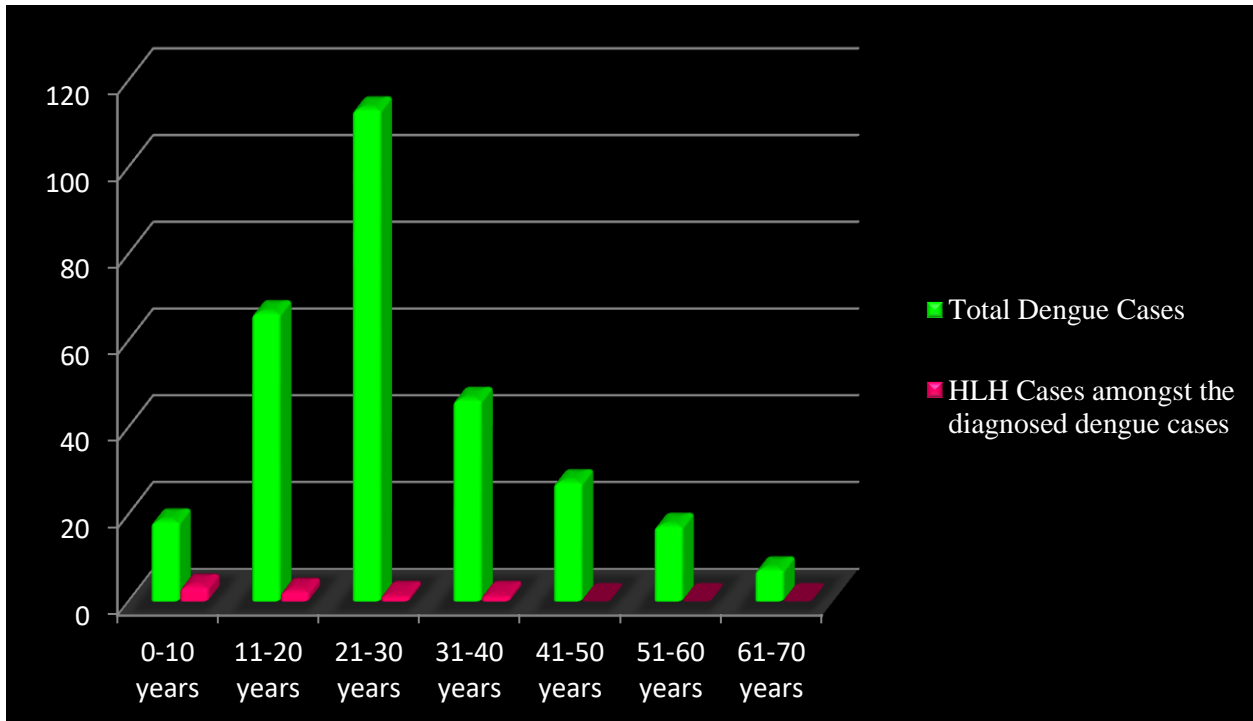


Figure 3 : Age and sex wise distribution of HLH cases in the present study.

Of the total 7 (2.3% of 294 cases of Dengue) cases of HLH, all the seven (100%) cases showed fever and bi-lineage cytopenia as the persistent findings, while 4 (57.1%) showed splenomegaly and hepatitis as other clinical findings.

All 7 (100%) cases had increased serum ferritin and triglyceride levels, while 3 (42.7%) out of 7 cases showed hemophagocytosis on bone marrow aspiration smears, while one case (14.2%) showed decreased plasma sodium level.

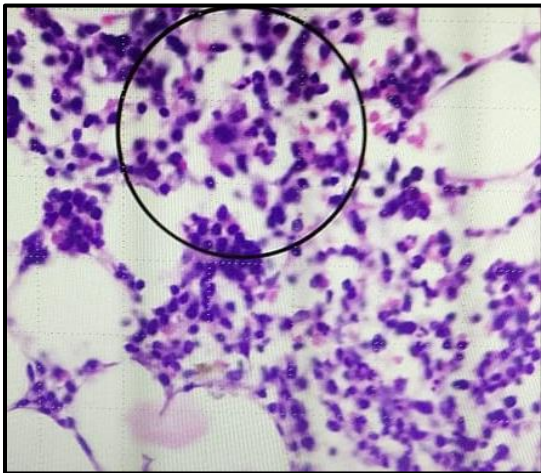


Figure 4: Hemophagocytes in bone marrow

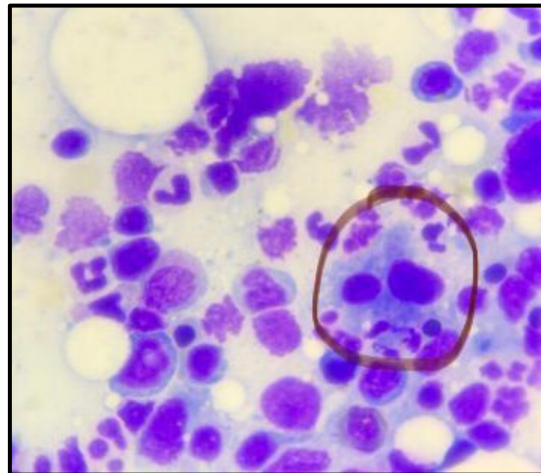


Figure 5: Phagocytic cells in Peripheral smear

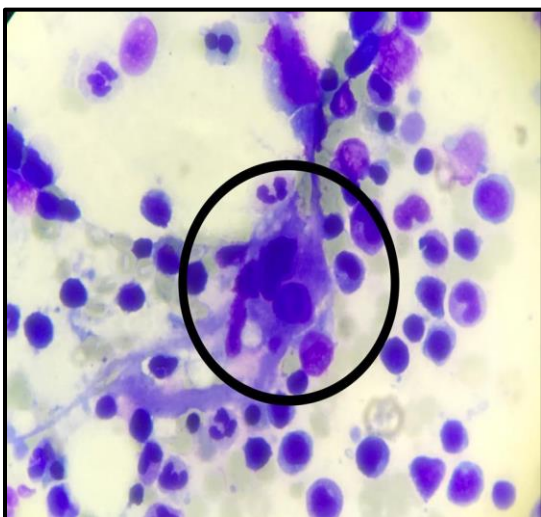


Figure 6: Phagocytic cells in Peripheral smear

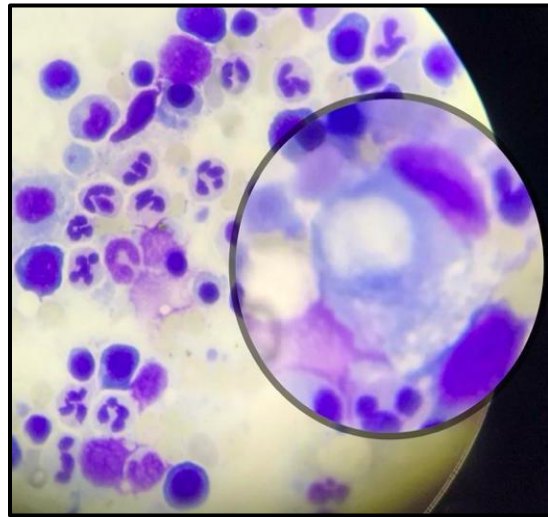


Figure 7: Phagocytic cells in Peripheral smear

DISCUSSION

Haemophagocytic Lymphohistiocytosis (HLH) is a complex clinical syndrome which has challenging issues pertaining to diagnosis and clinical management. HLH has inconsistent and varied clinical manifestations with no specific signs and symptoms, which are ostensibly found in other clinical conditions³. In early days of diagnosis of HLH, the diagnosis solely rested on five clinical and laboratory parameters such as fever, splenomegaly, bicytopenia, hypertriglyceridemia and/or hypofibrinogenemia, and evidence of hemophagocytosis^{2, 12}. In 2004 modifications of diagnostic criteria, three additional parameters were introduced by the Histiocyte Society² that included low or absent NK-cell-activity, hyperferritinemia, and high-soluble interleukin-2 receptor levels.. Five of these eight criteria are considered essential for the diagnosis of HLH. The NK cell activity and soluble IL-2 receptor quantification tests are not done in routine clinical practice since they require advanced studies at very few specialized centers and hence usefulness of these tests in routine practice is limited. Those patients meeting five of the eight criteria — splenomegaly, bicytopenia, fever, splenomegaly, bicytopenia (decrease in platelets and leucocytes) hyperferritinemia and presence of haemophagocytosis in the bone marrow were diagnosed as having secondary HLH². Hemophagocytosis, the phenomenon that lends its name to the nosological entity, is not a prerequisite for the clinical diagnosis of HLH⁶. This phenomenon was clinically discernible at some point during the follow-up in 3 (42.8%) cases of the present study. Nevertheless, inability to explore the possibility of or absence of hemophagocytosis should not be a hurdle in the diagnosis when the initial clinical manifestations are adequate to meet the other diagnostic criteria^{3,13}. The basic endeavour of clinical management of HLH is to prevent hyperactive immunological process to exacerbate the underlying primary clinical condition by the use of Immunosuppressants. Immunosuppressants used mainly include corticosteroids, Etoposide and Cyclosporine and are often the mainstay of treating this condition⁶ A short course of steroids has been used in all of the cases of HLH secondary to Dengue with good clinical outcome.

CONCLUSION

Haemophagocytic Lymphohistiocytosis (HLH) or Haemophagocytic syndrome is a complex clinical syndrome which is often associated with various infectious/inflammatory conditions, though primary HLH, often seen in children, is associated with various autoimmune, infectious and neoplastic processes.

The present study is an endeavour to study the presence of secondary HLH often in the context of microbial infections such as viral, bacterial and fungal infections and in the study, it is being demonstrated secondary HLH is one of the common and often fatal clinical syndrome occurring in patients suffering from Dengue. In certain endemic areas of Dengue like the one in which the present study was carried out, 2.3 per cent of Dengue patients had HLH which often led to many complications such as aberrant or overactive immune reactions leading to enhanced phagocytic process of histiocytes leading to severe cytopenias, hepatosplenomegaly/splenomegaly. Some of the complications such as severe thrombocytopenias often led to fatal haemorrhagic diathesis with serious implication for clinical recovery of Dengue patients. Though Dengue is clinically manageable in earlier stages, development of complications like HLH often made clinical outcome of the patients grave with outlook being optimistic in the form of early diagnosis of HLH and its clinical management with immunosuppressant medications.

REFERENCES

1. Max J Coppes, R., 2021. Lymphohistiocytosis (Hemophagocytic Lymphohistiocytosis): Practice Essentials, Background, Pathophysiology. [online] Emedicine.medscape.com. Available at: <<https://emedicine.medscape.com/article/986458-overview>>
2. Severe dengue due to secondary hemophagocytic lymphohistiocytosis: Ujjwayini Ray, Soma Dutta, Susovan Mondal, Syamasis Bandyopadhyay
3. Hemophagocytic lymphohistiocytosis: a caseseries of a Brazilian institution Daniela Guimarães Rocha Ferreira, Paulo do Val Rezende ,Mitiko Murao1 , Marcos Borato Viana, Benigna Maria de Oliveira
4. Review of haemophagocyticlymphohistiocytosis H R Freeman, A V Ramanan
5. Hemophagocytic lymphohistiocytosis (HLH) and related disorders Alexandra H. Filipovich
6. Kankanarachchi I., et al. "Haemophagocytic Lymphohistiocytosis (HLH) Secondary to Dengue Haemorrhagic Fever (DHF); A Paeditric Case Series". EC Paediatrics7.7 (2018): 638-640.
7. Dengue Infection Complicated by Hemophagocytic Lymphohistiocytosis: Experiences From 180 Patients With Severe Dengue Foong Kee Kan,¹ Cheng Cheng Tan,² Tatiana von Bahr Greenwood,^{3,4} Khairil E. Khalid,¹ Premaa Supramaniam,⁵ Ida Hed Myrberg,³ Lian Huat Tan,⁶ and Jan-Inge Henter

8. The global distribution and burden of dengue. Samir Bhatt, Peter W. Gething, Oliver J. Brady, Jane P. Messina, Andrew W. Farlow, Catherine L. Moyes, John M. Drake, John S. Brownstein, Anne G. Hoen, Osman Sankoh, Monica F. Myers, Dylan B. George, Thomas Jaenisch, G. R. William Wint, Cameron P. Simmons, Thomas W. Scott, Jeremy J. Farrar & Simon I. Hay.
 9. Dengue and haemophagocytic lymphohistiocytosis. MUZNAH KAPDI & IRA SHAH
 10. Development of a prognostic model for Macrophage Activation Syndrome in Systemic Juvenile Idiopathic Arthritis Prof. Angelo Ravelli
 11. Cytokine Storm Syndrome / edited Randy Q. Cron, E., 2021. Cytokine Storm Syndrome / edited by Randy Q. Cron, Edward M. Behrens. - Franklin. [online] Franklin.library.upenn.edu. Available at: <https://franklin.library.upenn.edu/catalog/FRANKLIN_9977619180203681>
 12. HLH-2004: Diagnostic and Therapeutic Guidelines for Hemophagocytic Lymphohistiocytosis Jan-Inge Henter, MD, PhD,^{1*} AnnaCarin Horne, MD,¹ Maurizio Arico', MD,² R. Maarten Egeler, MD, PhD,³ Alexandra H. Filipovich, MD,⁴ Shinsaku Imashuku, MD,⁵ Stephan Ladisch, MD,⁶ Ken McClain, MD, PhD,⁷ David Webb, MD,⁸ Jacek Winiarski, MD, PhD,⁹ and Gritta Janka, MD, PhD for the Histiocyte Society
 13. Cytokine Storm Syndrome / edited Randy Q. Cron, E., 2021. Cytokine Storm Syndrome / edited by Randy Q. Cron, Edward M. Behrens. - Franklin. [online] Franklin.library.upenn.edu. Available at: <https://franklin.library.upenn.edu/catalog/FRANKLIN_9977619180203681>
-