

International Journal of Scientific Research and Reviews

Sliding Hernia: A Case Report

Pithawa A.K.^{1*} and Sahani I S²

¹Professor & Head of Dept of Surgery, A.I.M.S., Bangar, Dewas (M.P.). India

²Associate Professor, Amaltas Institute of Medical Sciences, Dewas(M.P.). India

ABSTRACT:

Sliding hernia is a surgical entity which occurs usually in geriatric population. It accounts for approximately 3.4% of all groin hernia as per recent study. There is protrusion of retroperitoneal viscera, which also make part of wall of hernial sac. Therefore, surgery on sliding hernia carries high risk of injury to these structures. Here we report a case of huge irreducible sliding hernia containing ascending colon and caecum.

KEY WORDS: Hernia, Sliding, High Risk, Retroperitoneal Viscera.

Corresponding Author:

Dr AK Pithawa, MS, FAIS ,FMAS.

Professor & Head of Dept of Surgery,

Amaltas Institute of Medical Sciences, Bangar, Dewas (M.P.).

Tel-0731 4003255. Mob-8085952768.

Email- abhi.pithawa@yahoo.com

INTRODUCTION:

Inguinal hernia is a common surgical ailment for which a patient seek medical attention. However, sliding hernia is not a so common entity. A surgeon comes to know of diagnosis of sliding hernia on operation table, while operating on a case of inguinal hernia and finds that hernial sac contains retroperitoneal vicera which may be sigmoid colon, caecum or urinary bladder. Surgery on sliding hernia carries high risk of injury to these structures as they form part of wall of the hernial sac. Therefore, surgery on sliding hernia demands good surgical skill and precision.

EXPERIMENTAL SECTION:

A sixty five year old male presented with complains of swelling in right inguino-scrotal region of three year duration with dragging pain in groin. He also gave history of habitual constipation. There was no history of absolute constipation, fever, vomiting, jaundice, maleana, hematemesis, bleeding per rectum, dysuria, haematuria, chronic cough, haemoptysis, bony pains or worm infestation. There was no family history of similar disease or any congenital anomaly. On clinical examination vital parameters were found within normal limit with no pallor, icterus, pedal edema and lymphadenopathy. Per abdomen examination was normal, except there was a huge right sided Inguinal hernia extending up to testes (Fig-1). It was not possible to reduce the hernia therefore, deep ring occlusion test could not be done. Routine blood examination, X-ray chest, Plain X-ray abdomen and pelvis were normal. Patient was taken for surgery as elective case after preoperative preparation. Under spinal anaesthesia an incision was made 2.5 cm above and parallel to inguinal ligament. The incision was deepened until the Aponeurosis of external oblique was exposed. Superficial inguinal ring was identified and external Aponeurosis was divided in line with its fibres. The ileo-inguinal nerve was identified and preserved. Spermatic cord was separated from the hernial sac (Fig-2). The sac was palpated between two fingers and was found to be thick. Reduction of content back in peritoneal cavity was tried, but failed. Sac was thinnest at its tip where it was opened carefully and extended anteriorly. content and wall was examined. Content included Ascending colon and caecum, which was identified due to presence of taenia coli. Colon and Caecum also made posterior part of wall of the hernial sac (Fig-3). As it was not possible to reduce contents completely, as it formed part of wall, partial excision of sac was done, taking care not to injure caecum & colon forming posterior half of sac. Internal ring was freed of all adhesion and the sac was closed carefully and was reduced into peritoneal cavity. Orchidectomy was carried out after taking verbal consent from the patient and the wide internal inguinal ring was closed completely with prolene

(Fig-4). Strengthening of posterior inguinal wall was done by fixing a prolene mesh on it. Post operative period was uneventful. Patient was discharged on second postoperative day and sutures were removed on 8th postoperative day. Operative wound healed by first intension. Patient was reviewed at the end of one month, three months and six months and found to had no recurrence.



Fig-1. Huge Right sided Irreducible Inguinal Hernia

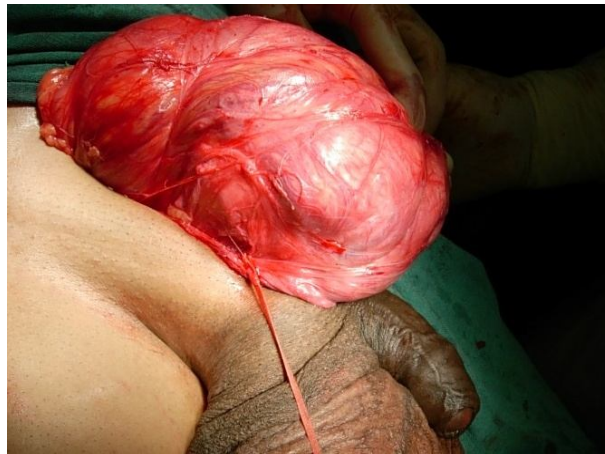

Fig 2. huge hernia on opening of inguinal canal.

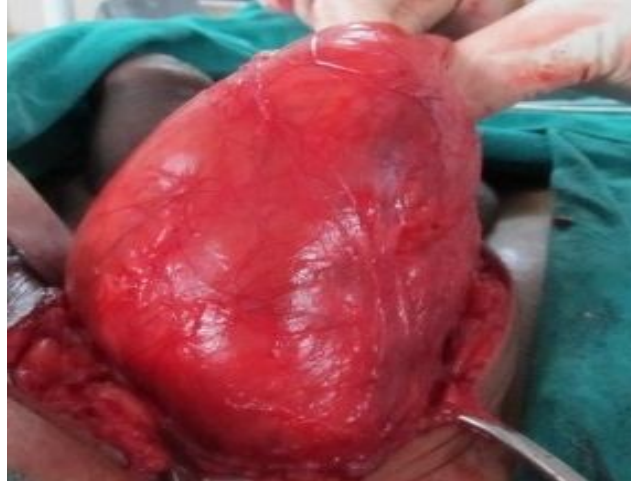

Fig 3. Hernial sac thinnest at the tip.

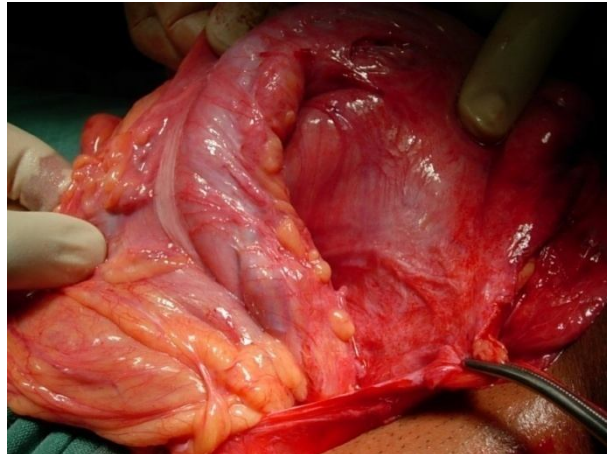


Fig 4. Ascending colon identified with taenia coli, making posterior wall of hernial sac.

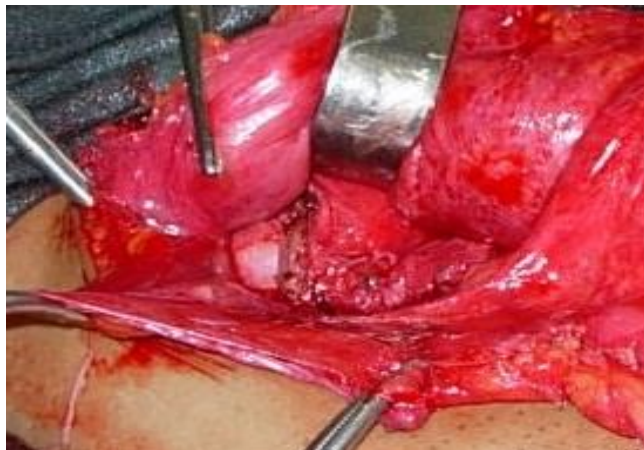

Fig 5. Wide, patulous internal inguinal ring.

DISCUSSION:

Sliding hernia is a protrusion of a retroperitoneal organ through an abdominal wall opening, in such a manner that organ itself or its peritoneal covering makes part of wall of the hernia sac¹. The organ may be Caecum, Appendix, colon, fallopian tube, ovary, ureter or urinary bladder. How does retroperitoneal structure 'Slide down' in the inguinal canal is not understood fully. However, in all cases of sliding hernia, the internal inguinal ring is found wide and patulous. One school of thought proposed "Pulling & Pushing Mechanism" whereby an enlarging inguinal hernia exerts pull on caecum and ascending colon to draw it down through a widened internal ring². Another school of thought proposed that layers of mesentery separate over long period of time, which causes posterior aspect of viscus to slide down through lax internal ring to form sliding hernia³. First accurate, specific and detailed description of sliding inguinal hernia was given by Italian surgeon, Professor Antonio Scarpa in his work "Sull'ernie" (On hernias)⁴. Frequency of sliding hernias is estimated at 3.4 % in recent study done in 2012⁵ while, previous studies estimated it about 6–8% of all elective inguinal hernia repairs⁶. Sliding hernia is very common in infant girls and it accounts for about 20% of all hernias in this group of patients. In these cases sliding hernia contains ovary and fallopian tube or fallopian tube alone⁷. Sliding hernia most commonly occur in geriatric male population. After the age of 50 years the incidence of sliding hernias is 3.5 times more frequent. The mean age of a hernia patient is estimated at 53.4 years and the mean duration of symptoms at 2.8 years⁸. It is difficult to diagnose sliding hernia preoperatively as there are no specific clinical sign indicating the possibility of sliding hernia and in most of occasion, diagnosis of sliding hernia is made during operation⁵. However, one must suspect sliding hernia when an geriatric patient presents with big irreducible hernia of long duration. Operation on Sliding inguinal hernia at time is very difficult and surgeon has to use his all experience and surgical skill to deal with it on OT table. It is imperative to excise whole of hernial sac and high ligation of sac in all other cases of inguinal hernia, however, same may lead to injury to organ in sliding hernia as part of sac is formed by the organ itself. Therefore, one should proceed very carefully while dissecting sliding hernia. First of all spermatic cord should be separated from hernial sac. Then transversalis fascia should be separated near the neck of sac. Sliding hernia with its wall should be identified then and gentle dissection of adhesion should be carried out to gradually return the viscus and sac to preperitoneal space. At times it is advisable to do partial excision of hernial sac only, to avoid inadvertent injury to structures. At the end, reconstruction of posterior inguinal wall should be carried out by tension free technique using prolene mesh. Two series of study has reported recurrence rate of 1%, while one study reported very high

recurrence of 55%^{6,9}. Morbidity and mortality is higher in sliding hernia cases than other variants of inguinal hernia. Mortality varies from 6% to 60% depending on age of patient, delay in diagnosis and the degree of vascular compromise¹⁰.

REFERENCE:

1. Victorino G.P., Arya J., and Bascom J. Inguinal hernia. in: A.H. Harken (Ed.) *Abernathy's surgical secrets*. Elsevier Mosby, Philadelphia; 2005.
2. Moschowitz AV, The rational treatment of sliding hernia. *Ann Surg*, 1925; 81:330.
3. Graham RR, The operative repair of sliding inguinal hernia of the sigmoid. *Ann Surg*, 1935; 102:784.
4. Scarpa A. *Sull'ernie: memorie anatomico-chirurgiche*. Stamperia Reale, Milan; 1809; 1820.
5. Komowski A L, Rodrigue J M, Kazi R. Sliding inguinal Hernia *international Journal of Surgery*.2012; 10(4): 206-208.
6. Ryan EA. An analysis of 313 consecutive cases of indirect sliding inguinal hernias. *Surg Gynecol Obstet* 1956; 102 (1):45–58.
7. Kaneko K., Ando H., and Tsuda M., New surgical procedure for sliding inguinal hernia repair in female infants and girls. *J Am Coll Surg*. 2002; 194: 544–546.
8. Browne J., Jamieson L., Lewsey J., van der Meulen J., Copley L., and Black N. Case-mix & patients' reports of outcome in Independent Sector Treatment Centres: comparison with NHS providers. *BMC Health Serv Res*. 2008; 8: 78.
9. Welsh DRJ. Repair of the indirect sliding inguinal hernias. *J AbdomSurg* 1969; 11:204–9.
10. McNealy RW, Lichtenstein ME, Todd MA, The diagnosis and management of incarcerated and strangulated hernias of the groin. *Surg Gynecol Obstet*, 1942; 74:1005.