

International Journal of Scientific Research and Reviews

Clinical significance of IDH1, EGFR, p53 and MIB1 in Astrocytoma Patients

Neha K. Bhalala¹, Nupur A. Patel² and Hemangini H. Vora^{3*}

¹Head of Immunohematology Laboratory, Cancer Biology Department, The Gujarat Cancer and Research Institute, Asarwa, Ahmedabad, India

ABSTRACT

Gliomas are tumors originating from glial cells, which show a range of aggressiveness depending on grade and stage. Therefore, this study evaluated clinical significance of IDH1, EGFR, p53 and MIB1 in grade I to IV astrocytoma patients. Seventy astrocytoma patients were enrolled in this study. Immunohistochemical localization of IDH1, EGFR, p53 and Ki67 was performed and correlated with clinicopathological parameters.

High IDH1 expression was found in 60% of astrocytoma patients which was significantly correlated with histological types($p=0.004$) and grade($p=0.004$) of astrocytoma tumors. High EGFR expression was found in 30% of astrocytoma patients. A trend of higher incidence of EGFR expression was observed in >15 years age group of patients. High p53 expression was found in 37% of astrocytoma patients which was significantly correlated with histological types($p=0.0001$) and histologic grade($p=0.0001$) of astrocytoma tumors. A significant higher p53 expression with respect to reduced disease-free survival was observed on univariate survival analysis($p=0.01$). MIB1 expression was found in 50% of astrocytoma patients which was significantly correlated with histological types($P=0.0001$) and histologic grade($p=0.0001$) of astrocytoma tumors. In multivariate survival analysis, p53 expression was entered at step 1. In conclusion High IDH1 and EGFR expressing astrocytoma can be benefitted with IDH1 inhibitors and anti EGFR therapy, respectively. Mutant p53 expression emerged as significant prognostic factor predicting reduce disease free survival indicated need of more effective treatment cause cellular apoptosis in high grade astrocytoma.

KEY WORDS: *IDH1, EGFR, p53, MIB1*

***Corresponding Author:**

Dr. Hemangini H. Vora

Associate Professor and Head of Immunohematology Laboratory,
Cancer Biology Department, GCRI, Asarwa, Ahmedabad, India

E mail : ihcgcri@hotmail.com; hemangini.vora@gcriindia.org. 079-22690000

INTRODUCTION

Astrocytomas are the most common type of glial tumor of the central nervous system. In 2007, the WHO projected a classification system for tumors of the central nervous system (CNS), categorizing a heterogeneous group of cancers into discrete types based on histopathologic criteria. Grade I tumors included pilocytic astrocytoma, grade II consisted of diffuse astrocytoma; grade III of anaplastic astrocytoma, and grade IV of glioblastoma (GBM). Within this category, glioblastoma is the most prevalent and malignant primary brain tumor. Glioblastoma can arise *de novo*, or in the course of progression from lower-grade lesions, but is evenly related with poor outcomes in spite of surgical resection, chemotherapy, and radiation therapy.² Recent genomic discoveries have provided new insight into glioma genesis and have identified key genetic alterations that have diagnostic, prognostic and predictive capacity. Several molecular classification schemes have been proposed to sort tumors into clinically meaningful categories to direct the treatment.³ However, creating therapy targeted towards these alterations has been made challenging by the redundancy of essential signal transduction pathways affected in these tumors, intratumoral heterogeneity, and the hypermutated profiles of recurrent tumors. IDH1 is an enzyme that catalyzes the oxidative decarboxylation of isocitrate to α -ketoglutarate.⁴ This reaction leads to NADPH production and is thought to play a role in cellular protection from oxidative stress.⁵ Among the most notable cancer genome-wide sequencing discoveries in recent years was the finding of mutation hot-spots in the isocitrate dehydrogenase (IDH) genes in grade II/III astrocytomas and oligodendrogliomas and in secondary glioblastomas.^{6,7} The epidermal growth factor receptor (EGFR) is a growth factor receptor that induces cell differentiation and proliferation upon activation.⁸ However, Alterations of this gene are considered as frequent driver mutations and are present in approximately 50% of Glioblastoma.^{9,10} p53 gene regulate gene expression to prevent mutations of the genome.¹¹ Thus, p53 can trigger different cellular mechanisms such as cell cycle arrest, apoptosis, differentiation, DNA repair, autophagy, and senescence.¹² MIB1 is also known as an antigen Ki-67. Ki-67 is a protein which is used as cellular marker for proliferation. During interphase, the Ki-67 antigen can be exclusively detected within the cell nucleus, whereas in mitosis most of the protein is relocated to the surface of the chromosomes.¹³

In light of this information, the present study determined IDH1, EGFR, p53 and MIB1 protein by immunohistochemical localization and evaluated their clinical significance in astrocytoma.

MATERIALS AND METHOD

Patients

This retrospective study was approved by Institutional Scientific and Ethics committees, included 70 brain cancer patients diagnosed and treated at the Gujarat Cancer & Research Institute between year 2016 and 2018. Among them 9(13%) patients were pediatric and whereas 61(87%) were adult. The primary treatment offered to all patients was surgery followed by adjuvant chemotherapy (Temozolomide) and/or radiotherapy (RT). The maximum follow-up period was 32 months with a median follow-up was 24 months and 6(9%) patients developed local recurrence and 5(8%) died due to cancer within study period. Patient's clinical and pathological characteristics are mentioned in Table 1.

Immunohistochemical localization

The tumor tissue blocks were obtained from the archives of Pathology Department of the Institute. 4µm thin sections were cut on microtome (Leica, Germany) and taken on 3-Aminopropyl triethoxysilane (APES) coated slides. Immunohistochemical localization of markers IDH1, EGFR, p53 and Ki67 were performed on formalin fixed paraffin embedded (FFPE) tissue blocks containing primary tumor and evaluated by Haematoxylin and Eosin (H&E) staining, on Ventana Benchmark XT autoimmunostainer using Ventana reagents (Ventana, USA). Briefly the protocol includes following steps of deparaffinization using EZ solution, antigen retrieval for 60 minutes using retrieval solution Cell conditioning1 (CC1), and incubation with Ultra View DAB inhibitor for 4 minutes, 100µl of respective primary antibodies of IDH1 (Polyclonal, 1:100, Invitrogen) for 32 minutes, EGFR (clone:3c6, RTU, Ventana) for 32 minutes, p53 (clone:SP5, 1:50, Thermo scientific) for 120 minutes, Ki-67 (clone:MIB1, 1:50, Dako) for 32 minutes, Ultra View HRP Multimer for 8 minutes, Ultra View DAB Detection kit for 8 minutes, counterstained with haematoxylin for 8 minutes, bluing reagent for 4 minutes and mounted with DPX.

Scoring

Two individual observers scored the sections. Cytoplasmic staining pattern was observed for IDH1, membranous staining for EGFR, and nuclear staining for p53 and MIB1. The sections were scored with semiquantitative scoring ranging from negative (no staining, Figure 1) to 3+ (1+: staining in <10% of cells, 2+: staining in 10% to 50% of cells, and 3+: staining in >50% of cells). For statistical analysis, negative and 1+ clubbed as low expression and 2+ and 3+ were clubbed as high expression.

Statistical Analysis

Statistical analysis was carried out using SPSS statistical software version 20 (SPSS Inc, USA). Mean, Standard error (SE) of mean and median were calculated and Pearson's Chi-square test with Pearson's correlation coefficient (r) was used to assess correlation and significance between two parameters. In case of patient number less than 5 in the cells of 2 x2 tables, Yates' Continuity correction value along with its significance was taken into consideration. Univariate survival analysis was carried out by Kaplan Meier method and Log Rank statistics was used to assess the prognostic significance of disease-free survival (DFS) and overall survival (OS). Multivariate survival analysis was performed using Cox regression model with forward stepwise (likelihood ratio) method. The Wald statistics and relative risk with 95% confidence interval (CI) for were used to evaluate the prognostic significance. P values ≤ 0.05 were considered to be significant.

RESULTE

IDH1 expression

Cytoplasmic IDH1 expression was observed in 60% of the tumors with an intensity of 1+ in 31%, 2+ in 36% and 3+ in 24% in patients brain cancer (Figure 2). The low IDH1 expression (0 or 1+) and high IDH1 expression (2+ or 3+) was observed in 40% and 60% of the brain tumors, respectively. A trend of higher incidence of IDH1 expression was observed with adult patients. A significant positive correlation of IDH1 expression was observed in diffuse astrocytoma, anaplastic astrocytoma and glioblastoma and pilocyticastrocytoma (p=0.004). Further a significant correlation of high IDH1 was noted with histologic grade (p=0.004, Table1).

Parameters	N (%) 70(100)	IDH1 Expression		EGFR Expression		p53 Expression		MIB1 expression	
		Low expression N (%) 28(40)	High expression N (%) 42(60)	Low expression N (%) 49(70)	High expression N (%) 21(30)	Low expression N (%) 44(63)	High expression N (%) 26(37)	Low expression N (%) 35(50)	High expression N (%) 35(50)
Age (Years)									
≤15 years	09(13)	06(67)	03(33)	09(100)	00(00)	06(67)	03(33)	07(78)	02(22)
>15 years	61(87)	22(36)	38(64)	40(66)	21(34)	38(62)	23(38)	28(46)	33(54)
Gender									
Male	50(71)	20(40)	30(60)	35(70)	15(30)	30(60)	20(40)	25(50)	25(50)
Female	20(29)	08(40)	12(60)	14(70)	6(30)	14(63)	06(37)	10(50)	10(50)
Histopathological types									
Pilocytic Astrocytoma	10(13)	09(90)	01(10)	09(90)	01(10)	10(100)	00(00)	10(100)	00(00)
Diffuse Astrocytoma	20(29)	08(40)	12(60)	15(75)	05(25)	18(90)	02(10)	19(95)	01(05)
Anaplastic Astrocytoma	20(29)	06(30)	14(70)	12(60)	08(40)	06(30)	14(70)	04(20)	16(80)
Glioblastoma	20(29)	05(25)	15(75) ^a	13(65)	07(30)	10(50)	10(50) ^c	02(10)	18(90) ^e
Histology Grade									
Grade I	10(13)	09(90)	01(10)	09(90)	01(10)	10(100)	00(00)	10(100)	00(00)
Grade II	20(29)	08(40)	12(60)	15(75)	05(25)	18(90)	02(10)	19(95)	01(05)
Grade III	20(29)	06(30)	14(70)	12(60)	08(40)	06(30)	14(70)	04(20)	16(80)
Grade IV	20(29)	05(25)	15(75) ^b	13(65)	07(30)	10(50)	10(50) ^d	02(10)	18(90) ^f

Table: 1Correlation of IDH1, EGFR,p53 and MIB1 expression with clinicopathological parameters

P value: ^a $\chi^2 = 13.12$, $r = 0.36$, $p = 0.004$,

^b $\chi^2 = 13.12$, $r = 0.36$, $p = 0.004$,

^c $\chi^2 = 22.88$, $r = 0.44$, $p = 0.0001$,

^d $\chi^2 = 22.88$, $r = 0.44$, $p = 0.0001$,

^e $\chi^2 = 46.20$, $r = 0.74$, $p = 0.0001$,

^f $\chi^2 = 46.20$, $r = 0.74$, $p = 0.0001$

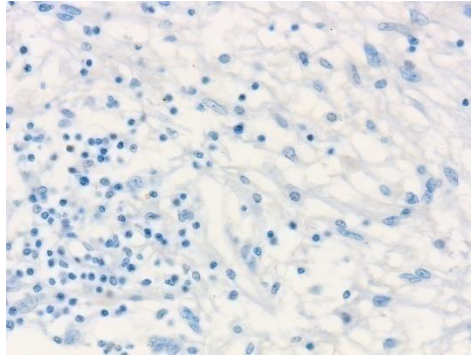


Figure 1. Negative staining

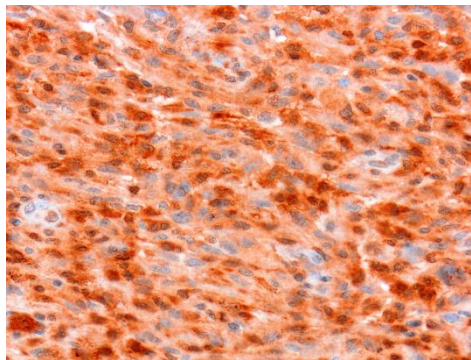


Figure 2. Cytoplasmic IDH1 staining in brain tumor cells.

IDH1 expression in relation to survival

In relation to Kaplan Meier univariate survival analysis, with respect to DFS, a trend of higher incidence of disease relapse was noted in high IDH1 expression with high grade astrocytoma tumor (17%,05/42) and low IDH1 expression with high grade astrocytoma tumor (09%,01/28; Log rank= 0.40, df=1, p=0.52, Table 2). With respect to OS, a similar trend was noted in high IDH1 expression with high grade astrocytoma tumor (14%,04/42) and low IDH1 expression with high grade astrocytoma tumor (09%,01/28; Log rank= 0.20, df=1, p=0.65, Table 3).

EGFR expression

Membranous EGFR expression was observed in 30% of the tumors with an intensity of 1+ in 07%,2+ in 09% and 3+ in 21% in patients brain cancer (Figure 3). Low EGFR expression (0 or 1+) and high EGFR expression (2+ or 3+) was observed in 70% and 30% of the brain tumors, respectively. No significant correlation was observed with clinical and pathological parameters (Table 1).

EGFR expression in relation to survival

According to Kaplan Meier univariate survival analysis, with respect to DFS, similar significant incidence of disease relapse was noted in high EGFR expression with high grade astrocytoma tumor (20%,03/21) and low EGFR expression with high grade astrocytoma tumor (12%,03/49; Log rank= 4.86, df=1, p=0.02, Table 2). With respect to OS, similar significant incidence of death was noted in high EGFR expression with high grade astrocytoma tumor (13%,02/21) and low EGFR expression with high grade astrocytoma tumor (12%,03/49; Log rank= 4.55, df=1, p=0.03, Table 3).

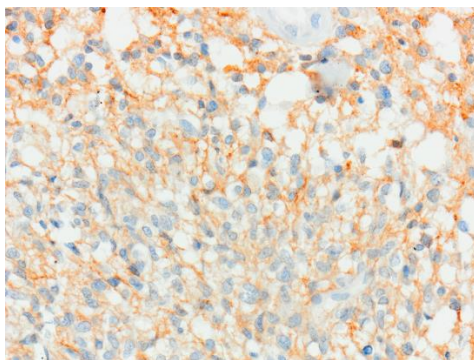


Figure 3.Membranous EGFR staining in brain tumor cells.

p53 expression

Nuclear p53 expression was observed in 37% of the tumors with an intensity of 1+ in 06%,2+ in 16% and 3+ in 21% in patients brain cancer (Figure 4). Low p53 expression (0 or 1+) and high p53 expression (2+ or 3+) was observed in 63% and 37% of the brain tumors, respectively. A significant higher incidence of p53 expression was observed with anaplastic astrocytoma and glioblastoma (p=0.0001) and with histologic grade III and grade IV (p=0.0001) as compared to their respective counterparts (Table 1).

p53 expression in relation to survival

According to Kaplan Meier univariate survival analysis, with respect to DFS, significant higher incidence of disease relapse was noted in high p53 expression with high grade astrocytoma tumor (21%,05/26) as compared to low p53 expression with high grade astrocytoma tumor (06%,01/44; Log rank= 5.44, df=1, p=0.02, Table 2). With respect to OS, significant higher incidence of death was noted in high p53 expression with high grade astrocytoma tumor (21%,05/26) as compared to low p53 expression with high grade astrocytoma tumor (00%,00/44; Log rank= 6.67, df=1, p=0.01, Table 3).

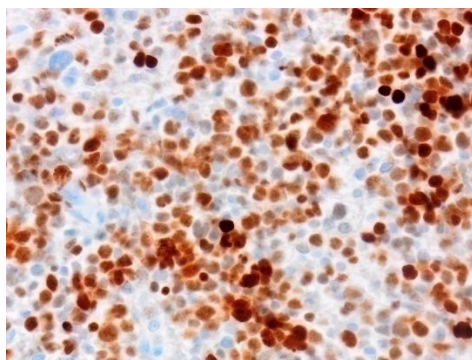


Figure 4. Nuclear p53 staining of brain tumor cells.

MIB1 expression

Nuclear MIB1 expression was observed in 50% of the tumors with an intensity of 1+ in 23%, 2+ in 34% and 3+ in 17% in patients brain cancer (Figure D). Low MIB1 expression (0 or 1+) and high MIB1 expression (2+ or 3+) was observed in 50% each of the brain tumors, respectively. A significant higher incidence of MIB1 expression was observed with anaplastic astrocytoma and glioblastoma ($p=0.0001$) and in high grade III and grade IV tumors ($p=0.0001$, Table 1).

MIB1 expression in relation to survival

According to Kaplan Meier univariate survival analysis, with respect to DFS, similar incidence of disease relapse was noted in high MIB1 expression with high grade astrocytoma tumor (15%, 05/35) and low MIB1 expression with high grade astrocytoma tumor (17%, 01/35; Log rank= 2.52, df=1, $p=0.11$, Table 2). With respect to OS, similar incidence of death was noted in high MIB1 expression with high grade astrocytoma tumor (12%, 04/35) and low MIB1 expression with high grade astrocytoma tumor (17%, 01/35; Log rank= 2.10, df=1, $p=0.14$, Table 3).

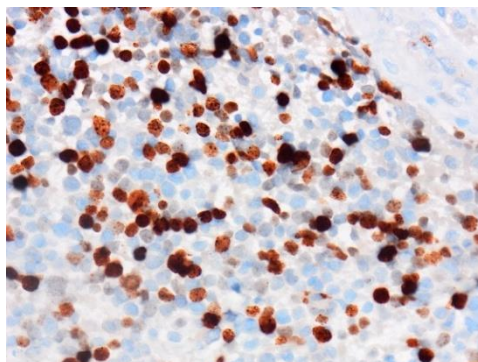


Figure 5. Nuclear MIB1 staining of brain tumor cells.

Table: 2 Univariate survival analysis for disease free survival.

Marker expression N (%)	Grade (N)	Remission N (%)	Relapsed N (%)
IDH1 low expression - 28 (40)	Low (17)	17(100)	00(00)
	High (11)	10(91)	01(09)
IDH1 high expression - 42 (60)	Low (13)	13(100)	00(00)
	High (29)	24(83)	05(17)
Log rank=0.40, df=1, p=0.52			
EGFR low expression - 49 (70)	Low (24)	24(100)	00(00)
	High (25)	22(88)	03(12)
EGFR high expression - 21 (30)	Low (06)	06(100)	00(00)
	High (15)	12(80)	03(20)
Log rank=4.86, df=1, p=0.02			
p53 low expression - 44 (63)	Low (28)	28(100)	00(00)
	High (16)	15(94)	01(06)
p53 high expression - 26 (37)	Low (02)	02(100)	00(00)
	High (24)	19(79)	05(21)
Log rank=5.44, df=1, p=0.02			
MIB1 low expression - 35 (50)	Low (29)	29(100)	00(00)
	High (06)	05(83)	01(17)
MIB1 high expression - 35 (50)	Low (01)	01(100)	00(00)
	High (34)	29(85)	05(15)
Log rank=2.52, df=1, p=0.11			

p value ≤ 0.05 is significant df =degrees of freedom

Table:3 Univariate survival analysis for overall survival.

Marker expression N (%)	Grade (N)	Alive N (%)	Dead N (%)
IDH1 low expression - 28 (40)	Low (17)	17(100)	00(00)
	High (11)	10(91)	01(09)
IDH1 high expression - 42 (60)	Low (13)	13(100)	00(00)
	High (29)	25(86)	04(14)
Log rank=0.20, df=1, p=0.65			
EGFR low expression - 49 (70)	Low (24)	24(100)	00(00)
	High (25)	22(88)	03(12)
EGFR high expression - 21 (30)	Low (06)	06(100)	00(00)
	High (15)	13(87)	02(13)
Log rank=4.55, df=1, p=0.03			
p53 low expression - 44 (63)	Low (28)	28(100)	00(00)
	High (16)	16(100)	00(00)
p53 high expression - 26 (37)	Low (02)	02(100)	00(00)
	High (24)	19(79)	05(21)
Log rank=6.67, df=1, p=0.01			
MIB1 low expression - 35 (50)	Low (29)	29(100)	00(00)
	High (06)	05(83)	01(17)
MIB1 high expression - 35 (50)	Low (01)	01(100)	00(00)
	High (34)	30(88)	04(12)
Log rank=2.10, df=1, p=0.14			

p value ≤ 0.05 is significant df =degrees of freedom

DFS, Disease free survival; OS, Overall survival

Markers expression in relation to treatment

In Kaplan Meier survival analysis, IDH1, EGFR, p53 and MIB1 expression were not found as an independent predictor of treatment response in relation to DFS and OS (Table 4).

Intermarker correlation

When IDH1, EGFR, p53 and MIB1 intercorrelated, a significant positive correlation of IDH1 expression was observed with EGFR expression (p=0.01) and high MIB1 expression (p=0.05). Also, a significant positive correlation of MIB-1 with EGFR expression (p=0.01) and p53 expression (p=0.0001) was noted (Table 5).

Multivariate survival analysis

In multivariate survival analysis by Cox regression model with forward stepwise (likelihood ratio) method p53 expression entered at step 1 as significant prognostic factor for predicting disease relapse (Table 6).

Table: 4 Markers expression in relation to treatment

Marker expression N(%)	Treatment offered	N	Remission N (%)	Relapsed N (%)	Alive N (%)	Dead N (%)
IDH1 low expression - 28 (40)	RT	01	01(100)	00(00)	01(100)	00(00)
	RT +TMZ	08	07(87)	01(13)	07(87)	01(13)
IDH1 high expression - 42 (60)	RT	02	02(100)	00(00)	02(100)	00(00)
	RT +TMZ	10	07(70)	03(30)	07(70)	03(30)
			Log rank= 0.78, df=1, p=0.37		Log rank= 1.86, df=1, p=0.17	
EGFR low expression - 49 (70)	RT	02	02(100)	00(00)	02(100)	00(00)
	RT +TMZ	12	10(83)	02(17)	09(75)	03(25)
EGFR high expression - 21 (30)	RT	01	01(100)	00(00)	01(100)	00(00)
	RT +TMZ	06	04(67)	02(33)	05(83)	01(17)
			Log rank= 0.90, df=1, p=0.34		Log rank= 2.63, df=1, p=0.10	
p53 low expression - 44 (63)	RT	01	01(100)	00(00)	01(100)	00(00)
	RT +TMZ	04	04(100)	00(00)	04(100)	00(00)
p53 high expression - 26 (37)	RT	02	02(100)	00(00)	02(100)	00(00)
	RT +TMZ	14	10(71)	04(29)	10(71)	04(29)
			Log rank= 1.29, df=1, p=0.25		Log rank= 0.17, df=1, p=0.68	
MIB1 low expression - 35 (50)	RT	01	01(100)	00(00)	01(100)	0(00)
	RT +TMZ	04	03(75)	01(25)	03(75)	01(25)
MIB1 high expression - 35 (50)	RT	02	02(100)	00(00)	02(100)	00(00)
	RT +TMZ	14	11(79)	03(21)	11(79)	03(21)
			Log rank= 0.001, df=1, p=0.97		Log rank= 1.81, df=1, p=0.17	

p value ≤0.05 is significant df=degrees of freedom

DFS, Disease free survival; OS, Overall survival

Table:5 Intercorrelation of IDH1, EGFR, p53 and MIB1 expression

	EGFRExpression		p53Expression		MIB1 Expression	
IDH1 expression	Low expression 49 (70)	High expression 21 (30)	Low expression 44 (63)	High expression 26 (37)	Low expression 35(50)	High expression 35(50)
Low expression (28)	24 (86)	04 (14)	19 (68)	09 (32)	18 (64)	10 (36)
High expression (42)	25 (60)	17 (40)	25 (60)	17 (40)	17 (40)	25 (60)
	$\chi^2= 5.48, r= 0.28, p= 0.01$		$\chi^2= 0.50, r= 0.08, p= 0.48$		$\chi^2= 3.81, r= 0.23, p= 0.05$	
p53 expression	Low expression 49 (70)	High expression 21 (30)				
Low expression (44)	31 (70)	13 (30)				
High expression (26)	18 (69)	08 (31)				
	$\chi^2= 0.01, r= 0.01, p= 0.91$					
MIB1expression	Low expression 49 (70)	High expression 21 (30)	Low expression 44 (63)	High expression 26(37)		
Low expression (35)	29 (83)	06 (17)	29(83)	06(17)		
High expression (35)	20 (57)	15 (43)	15(43)	20(57)		
	$\chi^2= 5.51, r= 0.28, p= 0.01$		$\chi^2= 11.99, r= 0.41, p= 0.0001$			

χ^2 = Chi-square, r =Correlation Coefficient, p value ≤ 0.05 is significant

Table: 6Multivariate survival analysis including all parameters

Patients	Step	Variables	Wald Statistic	df	P	Exp (B)	95% CI for Exp (B)	
							Lower	Upper
DFS N=64	1	p53	4.05	1	0.04	2.20	1.06	77.75

p value ≤ 0.05 is significant df =degrees of freedom

DISCUSSION

It has been reported that mutations of the isocitrate dehydrogenase (IDH1 and IDH2) gene are thought to occur early in glioma genesis and drive cancer progression.¹⁴ IDH1 mutations are also associated with aDNA hypermethylation phenotype, and result in barrier of histone demethylation and prevention of cell differentiation.^{15,16} In this study, IDH1 protein was evaluated by immunohistochemical localisation and 60% of astrocytoma tumour showed high IDH1 expression. The various studies showed the IDH1 positivity at the range of 11% -54%.^{17,18} Our study correlated IDH1 expression with clinicopathological parameters and found higher expression of IDH1 in adults (64%) as compared to paediatric patients (33%) which was accordance with the studies of Jaiswal et al (2018), Pollack et al (2011) and Bleeker et al (2009). These studies observed a higher degree of IDH-1 expression in adults (53%-68%) than in paediatric group (20% - 36%).^{19,20,21} While some studies shown that IDH1 expression was not found in paediatric group.^{22,23} The differential expression of IDH1 among different age group suggests activation of various age related pathways of tumorigenesis like PI3K pathway. In the present study, with histological subtypes IDH1 high expression was found in 10% of pilocytic astrocytoma, 60% of diffuse astrocytoma, 70% of anaplastic astrocytoma and 75% of glioblastoma. Similar to our findings, Ichimura et al also observed that mutations of IDH1 are rare in pilocytic astrocytoma.¹⁸ Mishra et al also observed that 59–90 % of diffuse astrocytoma, 28–82 % of anaplastic astrocytoma and 70-75% of secondary GBM showed IDH1R132H positivity.²⁴ We observed that IDH1 expression is significantly associated with histological type and histologic grade of astrocytoma tumor, which was in accordance to the study of Mishra et al, in which they observed a significant association between grade of astrocytoma and IDH1R132H expression.²⁴ IDH1 expression was observed to be higher in overall survival as compared to disease free survival, which was in accordance with the study by Hartmann et al, in which patients with tumors that possess mutations in IDH1 experience longer survival and have improved overall prognosis.²⁵

Amplification of the epidermal growth factor receptor (EGFR) gene has been reported in 40% of GBMs. Of these, 20–30% express a variant produced from the deletion of exons 2–7, EGFRvIII, a constitutively active receptor that is unable to bind ligand and results in continuous activation of cell growth and anti-apoptotic pathways.²⁶ Activation of EGFR in gliomas also occurs through gain of function mutations and double minute chromosomes.²⁷ In this study, membranous staining of EGFR was noted in 30% of astrocytoma. Several studies have shown EGFR positivity in the range of 35-50%.^{28,29} Our study observed EGFR expression in adults, which was in accordance with the study of Shelly et al (2016),

who observed EGFR amplified cases in the >40 year age group.³⁰ Also, EGFR gene amplification in adult GBMs can be seen across different age groups. In this study, EGFR expression was observed higher in grade III patients (40%) followed by grade IV (30%), grade II (25%) and grade I (10%) patients. Similar to our findings, Nishikawa et al (1994) have observed the frequency of EGFR gene amplification increases with increasing tumour grade and EGFR amplification is rare in grade II astrocytomas and is seen in only 4% of cases in their studies.³¹ In other studies glioblastomas showed highest expression of EGFR among all four grades and EGFR amplification is seen in 60% of cases.^{32,33} However, Mishra et al have shown that EGFR over-expression was not seen in any case of pilocytic astrocytoma, only 9% of diffuse astrocytoma showed EGFR over-expression and primary GBM show the highest percentage of EGFR protein expression in approximately 70% of cases.³⁴ They also showed that secondary glioblastoma, in contrast, show an expression profile similar to low grade gliomas with EGFR over-expression in 13% cases.³⁴ So, EGFR overexpression was associated with primary higher-grade of astrocytomas, suggesting that EGFR overexpression was associated with tumour aggressiveness and invasion.³⁴ In this study, EGFR expression was observed to be associated with reduced disease-free survival which was accordance with other reports in which high EGFR expression is associated with reduced overall survival.^{35,36, 37} Contrary to that some studies did not observe association of high expression of EGFR with poor prognosis in glioma.^{32,38,39,40}

Astrocytomas further acquire mutations in tumour suppressor gene Tp53 gene during malignant transformation.⁴¹ Mutated p53 encodes for a mutated nuclear protein which cannot be degraded easily and accumulates in the nucleus.⁴² Tumors with mutated p53 cannot tolerate genotoxic stress and as a result, tumor cells undergo apoptosis when treated with chemotherapeutic drugs and radiotherapy.⁴³ It has been considered that the increased expression of TP53 is a response to aggression to DNA.^{44,45,46} Cells with impaired function of p53 may develop genetic aberrations and lead to the development of malignancies.⁴⁷ This mutated TP53 can be detected by IHC and so overexpression of p53 is considered to be a surrogate marker for p53 mutation. In this study, nuclear staining of p53 was observed in 37% of astrocytoma. Further, no significant correlation of p53 expression was found with age and gender. However, p53 expression was observed significantly higher in high grade astrocytoma tumours (grade III and grade IV astrocytoma tumors) as compared to low grade astrocytoma tumors (grade I and grade II astrocytoma tumours). This result supports the view that p53 gene mutation is associated with the malignant progression from low-grade to high-grade astrocytomas rather than with tumor initiation or promotion.⁴⁸ Also, a significant association was found between p53 expression with glioblastoma and

anaplastic astrocytoma tumors which was in accordance with the study of Hwang et al (1999) and observed the results of immunostaining suggested that clonal expansion was associated with astrocytoma progression.⁴⁸ Contrary to that many studies indicated that p53 mutation occurs in the initial stages of tumour formation was reported by Louis et al.⁴² p53 gene and protein alterations could indeed be an early event in tumour progression, which may be associated with clinical aggressiveness. This study observed a significant association between disease free survival and p53 expression which was in accordance with the study of Jaros et al who showed that p53 protein overaccumulation was associated with reduced overall survival.³⁶

MIB1 is also known as antigen Ki-67. The Ki67 antigen is expressed at all stages of the cell cycle, except G0, thus it has been used to assess the growth fraction of human neoplasms. Assessment of Ki67 in central nervous system tumours has been intensely studied in gliomas.⁴⁹ The MIB-1 antibody is a true Ki67 equivalent and is readily detectable in paraffin-embedded materials using the microwave processed method.⁵⁰ Ever since, MIB-1 staining has been used for the diagnosis of human neoplasms in routinely formalin-fixed and paraffin-embedded histological materials. In this study, higher expression of MIB1 exhibited in 50% of astrocytoma. Many studies have shown that MIB1 labelling index was ranged from 1%-59%.^{51,52} This study showed that MIB-1 labelling index is not dependent on factors like age and gender, which was in the accordance of many studies.^{53,54,55} While, some studies have found that MIB-1 labelling index is dependent on age.^{56,57,58} In this study, MIB1 expression is significantly increased in glioblastoma and anaplastic astrocytoma patients as compared to diffuse astrocytoma patients whereas pilocytic astrocytoma do not exhibit MIB1 expression which is in accordance with the studies of Jaros et al and Matsumoto et al, where they found no significant difference in MIB1 LI between pilocytic and diffuse astrocytoma.^{36,51} While some studies have shown the opposite results compared to our study and have shown a very low LI for pilocytic astrocytoma and found significant difference in the distribution of MIB-1 LI between pilocytic and diffuse astrocytoma.^{53,59} In this study, MIB1 expression do not show a significant association between disease free survival and overall survival. The results of univariate survival analysis in another study revealed that both the progression-free survival and overall survival were significantly reduced in patients with anaplastic astrocytomas with Ki-67 LI >5%.⁶⁰

CONCLUSION

High IDH1 and EGFR expressing astrocytoma can be benefitted with IDH1 inhibitors and anti EGFR therapy, respectively. Mutant p53 expression emerged as significant prognostic factor predicting reduce disease free survival indicated need of more effective treatment cause cellular apoptosis in high grade Astrocytoma.

REFERENCES

1. Louis DN, Ohgaki H, Wiestler OD et al. The 2007 WHO classification of tumors of the central nervous system. *Actaneuropathologica*. 2007;114(2):97-109.
2. Grant R, Kolb L, & Moliterno J. Molecular and genetic pathways in gliomas: the future of personalized therapeutics. *CNS Oncology*. 2014; 3(2): 123-136.
3. Tanaka S, Louis DN, Curry WT et al. Diagnostic and therapeutic avenues for glioblastoma: no longer a dead end. *Nature reviews Clinical oncology*. 2013; 10(1):14-26.
4. Koshland Jr DE, Walsh K, LaPorte DC. Sensitivity of metabolic fluxes to covalent control. In *Current topics in cellular regulation*. Academic Press. 1985;27:13-22
5. Lee SM, Koh HJ, Park DC et al. Cytosolic NADP⁺-dependent isocitrate dehydrogenase status modulates oxidative damage to cells. *Free Radical Biology and Medicine*. 2002; 32(11): 1185-1196.
6. Parsons DW, Jones S, Zhang X et al. An integrated genomic analysis of human glioblastomamultiforme. *Science*. 2008; 321(5897): 1807-1812.
7. Yan H, Parsons DW, Jin G et al. IDH1 and IDH2 mutations in gliomas. *New England Journal of Medicine*. 2009; 360(8): 765-773.
8. Zhang H, Berezov A, Wang Q et al. ErbB receptors: from oncogenes to targeted cancer therapies. *The Journal of clinical investigation*. 2007; 117(8): 2051-2058.
9. Furnari FB, Fenton T, Bachoo RM et al. Malignant astrocytic glioma: genetics, biology, and paths to treatment. *Genes & development*. 2007; 21(21): 2683-2710.
10. Shinojima N, Tada K, Shiraishi S et al. Prognostic value of epidermal growth factor receptor in patients with glioblastomamultiforme. *Cancer research*. 2003; 63(20): 6962-6970.
11. Levine AJ, Lane DP. The p53 family. *Cold Spring Harbor Perspectives in Biology*. Cold Spring Harbor Laboratory Press. [ISBN 978-0-87969-830-0](#).
12. Vousden KH, Ryan KM. p53 and metabolism. *Nature Reviews Cancer*. 2009; 9(10): 691-700.

13. Cuylen S, Blaukop C, Politi AZ et al. Ki-67 acts as a biological surfactant to disperse mitotic chromosomes. *Nature*. 2016; 535(7611): 308-312.
14. Watanabe T, Nobusawa S, Kleihues P et al. IDH1 mutations are early events in the development of astrocytomas and oligodendrogliomas. *The American journal of pathology*. 2009; 174(4): 1149-1153.
15. Lu C, Ward PS, Kapoor GS et al. IDH mutation impairs histone demethylation and results in a block to cell differentiation. *Nature*. 2012; 483(7390): 474-478.
16. Figueroa ME, Abdel-Wahab O, Lu C et al. Leukemic IDH1 and IDH2 mutations result in a hypermethylation phenotype, disrupt TET2 function, and impair hematopoietic differentiation. *Cancer cell*. 2010; 18(6): 553-567.
17. Chaurasia A, Park SH, Seo JW et al. Immunohistochemical analysis of ATRX, IDH1 and p53 in glioblastoma and their correlations with patient survival. *Journal of Korean medical science*. 2016; 31(8): 1208-1214.
18. Ichimura K, Pearson DM, Kocalkowski S et al. IDH1 mutations are present in the majority of common adult gliomas but rare in primary glioblastomas. *Neuro-oncology*. 2009; 11(4): 341-347.
19. Jaiswal S, Chaudhary N, Prasad P et al. Expression of Isocitrate Dehydrogenase-1 (IDH-1) Mutant Protein in Gliomas. *Tech Neurosurg Neurol*. 2018;1(3): 1-6.
20. Pollack IF, Hamilton RL, Sobol RW et al. IDH1 mutations are common in malignant gliomas arising in adolescents: a report from the Children's Oncology Group. *Child's nervous system*. 2011; 27(1): 87-94.
21. Bleeker FE, Lamba S, Leenstra S et al. IDH1 mutations at residue p.R132 (IDH1R132) occur frequently in high grade gliomas but not in other solid tumors. *Human mutation*. 2009; 30(1): 7-11.
22. Antonelli M, Buttarelli FR, Arcella A et al. Prognostic significance of histological grading, p53 status, YKL-40 expression, and IDH1 mutations in pediatric high-grade gliomas. *Journal of neuro-oncology*. 2010; 99(2): 209-215.
23. Buccoliero AM, Castiglione F, Rossi Degl'Innocenti D et al. IDH1 mutation in pediatric gliomas: has it a diagnostic and prognostic value. *Fetal and pediatric pathology*. 2012; 31(5): 278-282.
24. Mishra S, Rathi KR, Shelly D et al. Immunohistochemical expression of IDH1R132H in Astrocytic tumours and its association with histopathological grade, TP53 and EGFR protein expression. *Annals of Pathology and Laboratory Medicine*. 2017; 4(5): A522-529.

25. Hartmann C, Meyer J, Balss J et al. Type and frequency of IDH1 and IDH2 mutations are related to astrocytic and oligodendroglial differentiation and age: a study of 1,010 diffuse gliomas. *Acta neuropathologica*. 2009; 118(4): 469-474.
26. Gan HK, Kaye AH, Luwor RB. The EGFRvIII variant in glioblastoma multiforme. *Journal of Clinical Neuroscience*. 2009; 16(6): 748-754.
27. Vogt N, Lefèvre SH, Apiou F et al. Molecular structure of double-minute chromosomes bearing amplified copies of the epidermal growth factor receptor gene in gliomas. *Proceedings of the National Academy of Sciences*. 2004; 101(31): 11368-11373.
28. Ohgaki H, Kleihues P. Genetic pathways to primary and secondary glioblastoma. *The American journal of pathology*. 2007; 170(5): 1445-1453.
29. Ohgaki H, Kleihues P. The definition of primary and secondary glioblastoma. *Clinical cancer research*. 2013; 19(4): 764-772.
30. Shelly D, Epari S, Arora I et al. Epidermal growth factor receptor (EGFR) gene amplification in high-grade gliomas: Western Indian tertiary cancer center experience. *Neurology India*. 2016; 64(1): 115-120.
31. Nishikawa R, Ji XD, Harmon RC et al. A mutant epidermal growth factor receptor common in human glioma confers enhanced tumorigenicity. *Proceedings of the National Academy of Sciences*. 1994; 91(16): 7727-7731.
32. Smith JS, Tachibana I, Passaniti SM et al. PTEN mutation, EGFR amplification, and outcome in patients with anaplastic astrocytoma and glioblastoma multiforme. *Journal of the National Cancer Institute*. 2001; 93(16): 1246-1256.
33. Hatanpää KJ, Burma S, Zhao D et al. Epidermal growth factor receptor in glioma: signal transduction, neuropathology, imaging, and radioresistance. *Neoplasia*. 2010; 12(9): 675-684.
34. Mishra S, Patnaik A, Majumdar S et al. Glioblastoma multiforme in a pediatric child. *Oncol J India*. 2018; 19 (2): 38-40.
35. Jiang H, Ren X, Zhang W et al. A new prognostic scoring scale for patients with primary WHO grade III gliomas based on molecular predictors. *Journal of neuro-oncology*. 2013; 111(3): 367-375.
36. Jaros E, Perry RH, Adam L et al. Prognostic implications of p53 protein, epidermal growth factor receptor, and Ki-67 labelling in brain tumours. *British journal of cancer*. 1992; 66(2): 373.

37. TiniP, Belmonte G, Toscano M et al. Combined epidermal growth factor receptor and beclin1 autophagic protein expression analysis identifies different clinical presentations, responses to chemo-and radiotherapy, and prognosis in glioblastoma. *BioMed research international*. 2015; 1-13.
38. Reis-Filho JS, Faoro LN, Carrilho C et al. Evaluation of cell proliferation, epidermal growth factor receptor, and bcl-2 immunoexpression as prognostic factors for patients with world health organization grade 2 oligodendroglioma. *Cancer*. 2000; 88(4): 862-869.
39. Bouvier-Labit C, Chinot O, Ochi C et al. Prognostic significance of Ki67, p53 and epidermal growth factor receptor immunostaining in human glioblastomas. *Neuropathology and applied neurobiology*. 1998; 24(5): 381-388.
40. Dorward NL, Hawkins RA, Whittle IR. Epidermal growth factor receptor activity and clinical outcome in glioblastoma and meningioma. *British journal of neurosurgery*. 1993; 7(2): 197-199.
41. Liu XY, Gerges N, Korshunov A et al. Frequent ATRX mutations and loss of expression in adult diffuse astrocytic tumors carrying IDH1/IDH2 and TP53 mutations. *Actaneuropathologica*. 2012; 124(5): 615-625.
42. Louis DN. The p53 gene and protein in human brain tumors. *Journal of neuropathology and experimental neurology*. 1994; 53(1): 11-21.
43. Bourdon JC, De Laurenzi, V, Melino, G et al. p53: 25 years of research and more questions to answer. *Cell death and differentiation*. 2003; 10: 397-399.
44. Collins VP. Mechanisms of disease: genetic predictors of response to treatment in brain tumors. *Nature Reviews Clinical Oncology*. 2007; 4(6): 362-374.
45. Furnari FB, Fenton T, Bachoo RM et al. Malignant astrocytic glioma: genetics, biology, and paths to treatment. *Genes & development*. 2007; 21(21): 2683-2710.
46. Sathornsumetee S, Reardon DA, Desjardins A et al. Molecularly targeted therapy for malignant glioma. *Cancer*. 2007; 110(1): 13-24.
47. Wen PY, Kesari S. Malignant gliomas in adults. *New England Journal of Medicine*. 2008; 359(5): 492-507.
48. Hwang SL, Hong YR, Sy WD et al. Expression and mutation analysis of the p53 gene in astrocytoma. *Journal of the Formosan Medical Association*. 1999; 98(1): 31-38.
49. Brown DC, Gatter KC. Monoclonal antibody Ki-67: its use in histopathology. *Histopathology*. 1990; 17(6): 489-503.

50. Gerdes J. Immunohistological detection of tumor growth fraction (Ki-67 antigen) in formalin-fixed and routinely processed tissues. *J Pathol.* 1992; 168: 85-86.
 51. Matsumoto T, Fujii, T, Yabe M et al. MIB1 and p53 immunocytochemistry for differentiating pilocytic astrocytomas and astrocytomas from anaplastic astrocytomas and glioblastomas in children and young adults. *Histopathology.* 1998; 33(5): 446-452.
 52. Ambrose MM, Khosla C, Ghosh M et al. Practical value of MIB-1 index in predicting behavior of astrocytomas. *Indian Journal of Pathology and Microbiology.* 2011;54(3): 520-525.
 53. Giannini C, Scheithauer BW, Burger PC et al. Cellular proliferation in pilocytic and diffuse astrocytomas. *Journal of Neuropathology & Experimental Neurology.* 1999; 58(1): 46-53.
 54. Roessler K, Bertalanffy A, Jezaň H et al. Proliferative activity as measured by MIB-1 labeling index and long-term outcome of cerebellar juvenile pilocytic astrocytomas. *Journal of neuro-oncology.* 2002; 58(2): 141-146.
 55. Bowers DC, Gargan L, Kapur P et al. Study of the MIB-1 labeling index as a predictor of tumor progression in pilocytic astrocytomas in children and adolescents. *Journal of clinical oncology.* 2003; 21(15): 2968-2973.
 56. Haapasalo H, Sallinen S, Sallinen P et al. Clinicopathological correlation of cell proliferation, apoptosis and p53 in cerebellar pilocytic astrocytomas. *Neuropathology and applied neurobiology.* 1999; 25(2): 134-142.
 57. Hsu DW, Louis DN, Efrid JT et al. Use of MIB-1 (Ki-67) immunoreactivity in differentiating grade II and grade III gliomas. *Journal of Neuropathology & Experimental Neurology.* 1997; 56(8): 857-865.
 58. Rodriguez-Pereira C, Suarez-Penaranda JM, Vazquez-Salvado M et al. Value of MIB-1 labelling index (LI) in gliomas and its correlation with other prognostic factors: A clinicopathologic study. *Journal of neurosurgical sciences.* 2000; 44(4): 203-209.
 59. Ralte AM, Sharma MC, Karak AK et al. Clinicopathological features, MIB-1 labeling index and apoptotic index in recurrent astrocytic tumors. *Pathology & Oncology Research.* 2001; 7(4): 267-278.
 60. Korshunov A, Sycheva R, Golanov A. The prognostic relevance of molecular alterations in glioblastomas for patients age < 50 years. *Cancer.* 2005; 104(4): 825-832.
-