

International Journal of Scientific Research and Reviews

A Clinical Study of Flexible Intramedullary Nailing in Femoral Diaphyseal Fractures in Skeletally Immature Patients.

Dr Manjunatha V^{1*} and Dr Anurag Jain²

¹ESICMC and PGIMSR, Rajajinagar, Bangalore-560010, India.

²VMMC and Safdarjung hospital, New Delhi-110029, India

ABSTRACT

The treatment of pediatric and adolescent femur fractures remains controversial. Differences of opinion about treatment are greatest for patients between the age group of 6 and 16 years. Flexible intramedullary nailing has emerged as an accepted procedure for femoral diaphyseal fracture in skeletally immature patients. Despite its excellent reported results, orthopaedic surgeons remain divided in opinion regarding its usefulness.

We did a prospective hospital based study including 24(21 male, 3 female) femoral diaphyseal fractures in skeletally immature patients presenting to our hospital treated by flexible intramedullary nailing. The results were evaluated based on Flynn's criteria. All 24 patients were available at follow-up of 24 months. Grade 3 callus formation according to Anthony's scoring system was seen at a mean time of 9 weeks. Mean duration of hospital was 9.4 days. The results were excellent in 20 cases, satisfactory in 3 cases and poor in 1 case. Hence we conclude that flexible intramedullary nailing is a simple and effective way of fixation with excellent functional results and minimal complications in femoral diaphyseal fractures in skeletally immature patients.

KEY WORDS: Flexible intramedullary nailing, femoral diaphyseal fracture, skeletally immature patients.

***Corresponding author**

Dr Manjunatha V

Senior resident, MBBS, Dip orthopedics, DNB Orthopedics.

ESICMC and PGIMSR, Rajajinagar, Bangalore-560010, India.

Email: vmj819@gmail.com, anurag615@rediffmail.com

INTRODUCTION

Femoral shaft fractures account for 1.6% of all pediatric bony injuries.¹ There is little controversy over the treatment of adult femoral shaft fractures with intramedullary nail fixation.² Similarly, there is little controversy over the treatment of infants and toddlers with femoral shaft fractures by using spica casting, but the treatment of pediatric and adolescent (age 6 to 16 years) femur fractures remains controversial. Time and experience of many clinicians have shown that children with diaphyseal femur fracture do not always recover with conservative treatment. Angulation, malrotation and shortening are not always corrected effectively.³ The management of pediatric femoral shaft fractures gradually has evolved towards a more operative approach in the past decade. This is because of a more rapid recovery and reintegration of the patients and a recognition that prolonged immobilization can have a negative effect even in children.⁴ Elastic internal fixation in the form of flexible intramedullary nailing provides a healthy environment for fracture healing with some motion leading to increased callus formation.⁵ Flexible intramedullary nailing in the pediatric population is simple, effective and minimally invasive. It allows stable fixation, rapid healing and a prompt return of the child to normal activity.⁶ The present study was undertaken to evaluate the functional outcome of flexible intramedullary nailing in femoral diaphyseal fractures in skeletally immature patients in the age group of 6 to 16 years.

MATERIALS AND METHODS:

This is a prospective study where 24 children (21 males, 3females) in the age group of 6-16 years (mean age 9.2years) with femoral diaphyseal fractures were stabilized with flexible intramedullary nails. Mode of injury was road traffic accident in 22 cases (92%). Right side was affected in 15 cases (62%). Level of fracture was proximal third in 7 cases (29%) and middle third in 17 cases (71%). Most of the cases were operated within 5 days (18 patients, 75%) of injury. After anaesthetizing, patient was put on traction table in supine position. Two flexible nails of identical sizes were used (Titanium elastic nails in 12 cases and Ender's nail in 12 cases). Nail length was decided by measuring from tip of greater trochanter to medial knee joint line, then subtracting 2cms for lateral nail and 4cms for medial nail. Nail diameter was decided as 40% of internal diameter at isthmus of contralateral femur calculated radiologically. Fractures were reduced by fluoroscopic guidance. Nails were inserted in retrograde fashion with 1cm medial and lateral incision 2-3 cms above the physis (roughly corresponds to superior border of patella) [Figure 1]. The nails were prebent sufficiently so that the apex of the bowed nails was

at the same level at the fracture site so that good recoil took place. Open reduction was required in two patients as reduction was not possible and both these patients had presented on tenth and eleventh day after injury to hospital. The nails were advanced proximally such that the medial nail rested in metaphysis of femoral neck and lateral under greater trochanter, both 1 cm distal to physis [Figure 2]. Postoperatively the patients were made to sleep in supine position with pillow under operated limb. Any sort of immobilization was not used. Patient was advised early active pain free mobilization of hip and knee. Non weight bearing mobilization with crutches was started on fifth day under strict supervision of parents. Patients were followed up at 6, 8, 10, 12, 24 weeks and 1 year. Each patient was assessed clinically and radiologically. Observations were made regarding the alignment of the fracture, the range of motion of knee and hip, limb length discrepancy, varus and valgus angulation of femur and assessment of result was based on Flynn's⁷ criterion [Table 1].

Table 1: Flynn et al⁷ criteria for assessment of results

	Excellent	Satisfactory	Poor
Limb length discrepancy	<1cm	<2cm	>2cm
Malalignment	Up to 5⁰	5⁰-10⁰	>10⁰
Pain	None	None	Present
Complication	None	Minor	Major and or lasting morbidity

Weight bearing was allowed when radiological evidence of union was evident as assessed by Anthony's scale⁸ [Table 2] for grading callus formation.

Table 2: Anthony et al⁸ scale for grading callus formation.

Grade 0	No identifiable fracture healing.
Grade 1	Primary bone healing with little or no periosteal new bone formation.
Grade 2	Periosteal new bone formation on two sides of femur.
Grade 3	Periosteal new bone formation on three to four sides of femur.

Partial weight bearing in patients with grade 2 callus formation and complete weight bearing in patients with grade 3 callus formation.

RESULTS:

In our study road traffic accident was the mode of injury in 22 cases (92%) and 2 cases (8%) were due to fall from height. During surgery reduction was achieved by closed method in 22 cases (92%) and in 2 cases (8%) reduction was possible after opening the fracture site, both these cases presented 7 days or later after trauma to hospital. Difficulty in passing medial nail into proximal fragment was noted in 3 cases (13%). The mean duration of surgery was 65min (30min-120min). The mean hospital stay was 9.4 days (8-12 days). Radiological union according to Anthony's scale⁸ was achieved in mean time of 8.16 weeks (6-10 weeks). Complete range of motion at hip and knee joints was achieved at mean time of 7 weeks (6-12 weeks). Complications that were noted in our study were limb lengthening of 5mm in 2 cases (8%) and 10mm in 4 cases (17%), varus angulation of 5 degree in 4 cases (17%), skin site irritation and pain in 4 cases (17%) and bursa formation in 2 cases (8%). None of the patients developed major complication like infection, delayed union, nonunion or implant failure, however skin penetration occurred in 1 case (4%) at 10 months, this patient initially developed skin site irritation and bursitis following which skin penetration occurred. Implant was removed in this case and postoperatively wound healed well with infection. The results were excellent in 20 cases (83%), satisfactory in 3 cases (13%) and poor in 1 case (4%) based on Flynn's criteria⁷ [Table 3]. All 3 in satisfactory group had skin irritation with one them developing bursitis and one patient in poor group had developed skin penetration.

Table 3: Result based on Flynn et al⁷ criteria.

Result	No of Cases	Percentage
Excellent	20	83
Satisfactory	3	13
Poor	1	4

DISCUSSION:

Although femoral shaft fractures constitute 1.6% of all pediatric fractures, the choice of treatment has remained a challenge to the orthopaedic surgeon especially in the age group of 6 to 16 years. Conservative treatment was the preferred method for diaphyseal fractures in children and adolescents, but to avoid prolonged immobilization, loss of school days and for better nursing care the

operative approach has been gaining popularity in last two decades. Each of the surgical methods described have specific advantages and potential complications that must be appreciated by the treating surgeon. Plating of femoral shaft fracture offers rigid fixation, it requires a larger exposure with the potential for increased blood loss and scarring. It is a load bearing device and refracture is a risk. Antegrade nailing techniques have shown a risk of proximal femoral deformities and avascular necrosis of the femoral head.^{6,9} The external fixator provides good stability and early mobilization, but is associated with the risk of pin tract infections and it takes a longer time for weight bearing.^{10,11}

Elastic internal fixation in the form of flexible intramedullary nailing provides a healthy environment for fracture healing with some motion leading to increased callus formation.⁵ Flexible intramedullary nailing in the pediatric population is simple, effective and minimally invasive. It allows stable fixation, rapid healing and a prompt return of the child to normal activity.⁶

Similar to our study road traffic accident was the leading cause of injury constituting 15 cases (75%) in Bar-on E et al¹² study and 14 cases (63.6%) in KC Saika et al¹³ study.

Reduction was achieved by closed method in 22 cases (92%) and in 2 cases fracture was opened in our study. In 5 (6.41%) fractures, open reduction was done to facilitate passing the nail across the fracture site in Heinrich SD et al³ study and open reduction was required in 3 cases (13.6%) in KC Saikia et al¹³ study due to soft tissue interposition.

Difficulty in passing medial nail into proximal fragment was noted in 3 cases (13%) due to lack of space for maneuvering the medial nail, the problem was solved by introducing the medial nail first with hip in slight abduction. Difficulty in negotiating nail into the proximal fragment was noted even by KC Saika et al¹³.

The mean duration of surgery was 65 min in our study and 70 min in KC Saika et al¹³ study.

Average stay in the hospital was 9.4 days in our study which is comparable to 12 days in Kalenderer O et al¹⁴ study and 9.8 days in KC Saika et al¹³ study. Griesberg J et al¹⁵ noted average hospital stay of 6 days in flexible intramedullary nail versus 29 days in hip spica casting group. Gross RH et al¹⁶ noted average hospitalization of 18.7 days in their study on cast brace management of femoral shaft fractures.

Grade 3 callus formation according to Anthony et al⁸ scale was seen at an average of 8.16 weeks in our study. The fractures in all patients healed within 12 weeks in Cramer K E et al⁶ study. Radiological union was achieved in all cases in a mean time of 8.7 weeks in KC Saika et al¹³ study.

Complete range of motion of hip and knee joints was obtained at a mean duration of 7 weeks in our study. Bar-On E et al¹² noted 20° loss of internal rotation at the hip in one patient treated with external fixation. Flynn J M et al⁷ noted one case of knee stiffness in patients treated with spica casting which required manipulation under anesthesia. Functional range of movement of knee was achieved in an average of 8.3 weeks in KC Saikia et al¹³ study.

Limb lengthening of 5mm in 2 cases (8%) and 10mm in 4 cases (17%) were noted in our study, none of them were clinically significant. Cramer KE, et al⁶ noted average limb lengthening of 7mm (range 1-19mm) in their study. Clinically significant limb discrepancy (> 2cm) did not occur in any patient in their study. KC Saika et al¹³ noted limb lengthening of less than 1.5cms in 3 cases.

Varus angulation of 5 degree was noted in 4 cases (17%) in our study, all 4 of them were fractures of proximal 1/3rd of femur. Heinrich SD et al³ reported 5° of varus angulation in one child in their study and 11 % of fractures had an average varus or valgus malalignment of 6°. Cramer KE et al⁶ reported 4 children had less than 15° angulation in any plane and 49 children had no angulations in their study. KC Saikia et al¹³ noted varus angulation of 12° and 6° degree in 2 patients and valgus angulation of 15° degree in 1 patient.

Skin irritation and pain occurred in 4 cases (17%) and bursa formation was noted in 2 cases (8%). KC Saika et al¹³ noted skin site irritation in 4 cases (18.18%).

Nail tip penetrated through the skin in 1 case (4%) in our study and KC Saika et al¹³ noted skin penetration in 2 cases (9%).

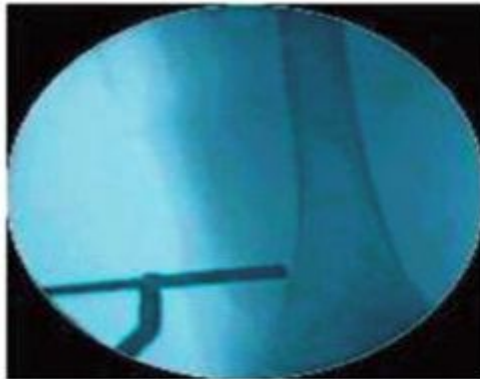
The results based on Flynn et al⁷ criteria were excellent in 20 (83%), satisfactory in 3 (13%) and poor in 1 (4%) case in our study. Flynn et al⁷ noted excellent in 39 cases (67.13%), satisfactory in 18 (31%) and poor result in 1 case (1.7%). In KC Saikia et al¹³ group 13 patients (59%) had excellent result, 6 (27.2%) had successful and 3 patients (13.6%) had poor results as assessed by Flynn et al criteria.

Table 4: Master chart.

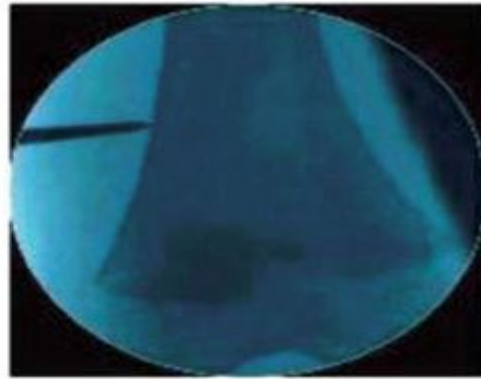
Age/ Sex	Side	Duration of hospital stay	Difficulty during Operation	Duration of Surgery	Complications	Callus formati on	Range of Motion (HIP & KNEE)	Follow- up in months
6yrs/ Male	Rig ht	9 days	None	45min	None	Grade 3 at 6wks.	Complete at 6 wks.	22
8yrs/ Male	Lef t	11 days	None	60min	10mm longer	Grade 3 at 6wks.	Complete at 6 wks.	17
9yrs/ Male	Rig ht	12 days	Difficulty in passing medial nail.	90min	Pain and Skin irritation	Grade 3 at 6wks.	Complete at 12 wks.	20
7yrs/ Male	Rig ht	11 days	Difficulty in passing medial nail.	45min	None	Grade 3 at 8wks.	Complete at 6 wks	19
8yrs/ Male	Lef t	10 days	None	30min	10mm longer, 5 degree varus	Grade 3 at 6wks.	Complete at 6 wks.	19
12yr s/Ma le	Rig ht	8 days	Difficulty in passing medial nail.	60min	None	Grade 3 at 10 weeks	Complete at 6 wks.	18
10yr s/Ma le	Lef t	9 days	Difficulty in reducing fracture.	120min	Pain , Skin irritation, Bursa and Skin Penetration	Grade 3 at 8 weeks	Complete at 12 wks.	15
6yrs/ Fem ale	Rig ht	10 days	Difficulty in reducing fracture.	120min	5 degree varus, Pain and Skin irritation	Grade 3 at 10 weeks	Complete at 12 wks.	14
11yr s/Ma le	Rig ht	9 days	None	90min	10mm longer	Grade 3 at 10 weeks	Complete at 6 wks.	16
7yrs	Lef t	10 days	None	60min	10mm longer	Grade 3 at 6wks.	Complete at 6 wks.	17
8yrs/ Fem ale	Rig ht	9 days	None	90min	None	Grade 3 at 8 weeks	Complete at 6 wks.	16
12yr	Lef	8 days	None	60min	5mm longer	Grade 3	Complete at 6	15

s/Female	t					at 8 weeks		
9yrs/Male	Right	10 days	None	60min	None	Grade 3 at 10 weeks	Complete at 6 wks.	15
16yrs/Male	Right	9 days	None	60min	5 degree varus	Grade 3 at 10 weeks	Complete at 6 wks.	14
10yrs/Male	Left	10 days	None	90min	None	Grade 3 at 10 weeks	Complete at 6 wks.	15
8yrs/Male	Right	11 days	None	60min	None	Grade 3 at 8 weeks	Complete at 6 wks.	15
10yrs/Male	Left	10 days	None	60min	None	Grade 3 at 10 weeks	Complete at 6 wks.	14
6yrs/Male	Left	8 days	None	45min	Pain, Skin irritation and Bursa	Grade 3 at 6wks.	Complete at 12 wks.	14
8yrs/Male	Right	9 days	None	30min	5mm longer	Grade 3 at 6wks.	Complete at 6 wks.	13
10yrs/Male	Right	9 days	None	60min	5 degree varus	Grade 3 at 10 weeks	Complete at 6 wks.	14
14yrs/Male	Right	8 days	None	90min	None	Grade 3 at 10 weeks	Complete at 6 wks.	13
7yrs male	Right	9 days	None	60min	None	Grade 3 at 8 weeks	Complete at 6 wks.	13
8yrs/Male	Left	9 days	None	30min	None	Grade 3 at 6wks.	Complete at 6 wks.	12
10yrs/Male	Right	8 days	None	45min	None	Grade 3 at 10 weeks	Complete at 6 wks.	12

FIGURES:

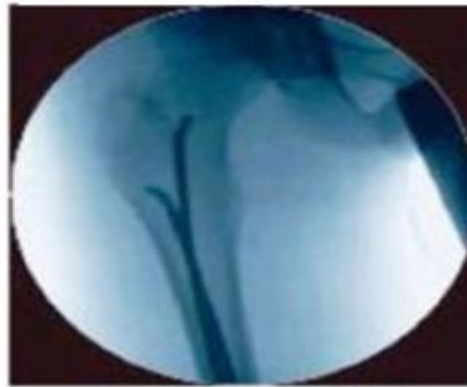
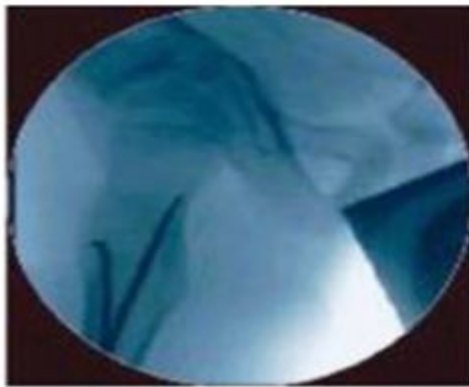


Entry point drilled



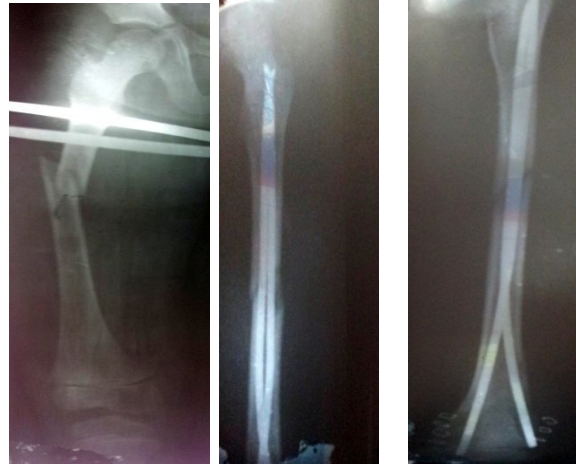Entry point widened with bone awl

Figure 1: Entry point.



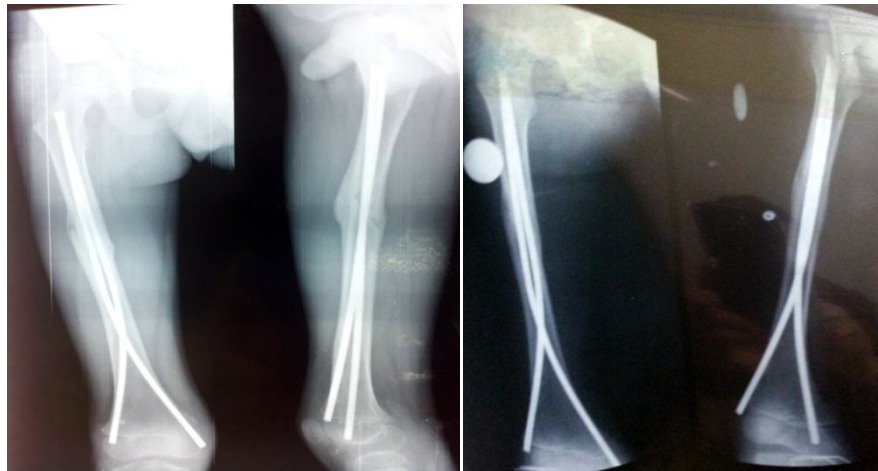Medial nail passed into neck of femur, lateral nail passed upto greater trochanter

Figure 2: Final position of nails.



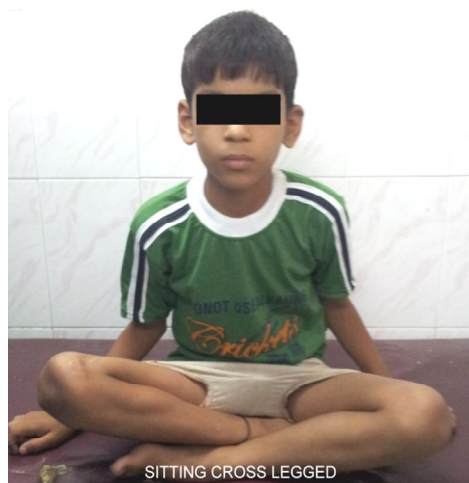PRE OPERATIVE

IMMEDIATE POST OPERATIVE

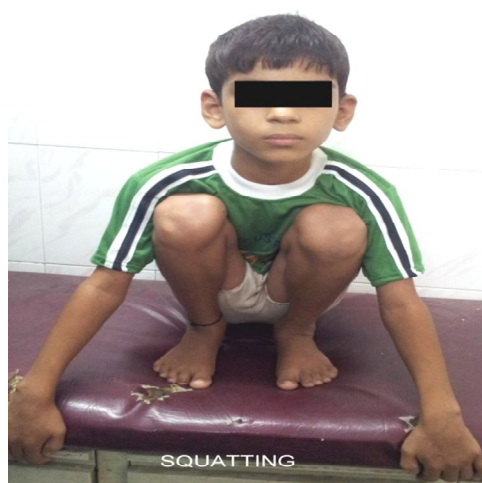

3 MONTHS POST OP

1 YEAR POST OP



SITTING CROSS LEGGED



SQUATTING

FIGURE 3: case 19 - 8yr, male, treated by closed reduction and titanium elastic nail.

CONCLUSION:

Based on our experience and results, we conclude that flexible intramedullary nailing is a simple and effective way of fixation with excellent functional results and minimal complications in femoral diaphyseal fractures in skeletally immature patients.

COMPETING INTERESTS:

The authors declare that they have no competing interests.

ACKNOWLEDGEMENT:

I sincerely thank Dr Harmit Singh and Dr Umed Singh for their guidance throughout the period of study.

REFERENCES:

1. Scherl SA, Miller L, Lively N, Russinof S, Sullivan M Tornetta P III. et al. "Accidental and nonaccidental femur fractures in children". *Clinical Orthopaedic and Related Research* 2000; 376:96-105.
2. Momberger N., Stevens P., Smith J., Santora S, Scott S and Anderson J. "Intramedullary nailing of femoral fractures in adolescents". *Journal of Pediatric Orthopaedics* 2000; 20: 482-484.
3. Heinrich SD., Drvaric DM., Karr K. and Macevan GD. "The operative stabilization of pediatric diaphyseal femur fractures with flexible intramedullary nails: A prospective analysis". *Journal of Pediatric Orthopaedics* 1994; Vol.14: 501-507.
4. Carey TP. and Galpin RD. "Flexible intramedullary nail fixation of femoral fractures". *Clinical Orthopaedic and Related Research* 1996; 332: 110-118.
5. Kasser JR. and Beaty JH. "Femoral shaft fractures". In: Beaty JH. And Kasser JR eds. *Rockwood and Wilkin's fractures in children, 5th edition*, Philadelphia, Lippincott, Williams and Wilkins, 2001; 941-980.
6. Cramer KE., Tornetta P. III, Spero CR, Alter S, Miraliakbar H, Teefey J. "Ender rod fixation of femoral shaft fracture in children". *Clinical Orthopaedic and Related Research* 2000; 376: 119-123.
7. Flynn JM, Hreske T, Reynolds RAK et al Titanium elastic nail for paediatric femur fractures. *J. Pediatr orthopaedics* January/February 2001; 21(1):4-8.
8. Anthony A. Stans, Raymond T. Morrisy, Stephen E. Renwick: "Femoral shaft fracture treatment in patients age 6-16 years". *Journal of Pediatric Orthopedics* 19(2): 222-228, March/April 1999.

9. Townsend DR and Hoffinger S. "Intramedullary nailing of femoral shaft fractures in children via the trochanteric tip". *Clinical Orthopaedic and Related Research* 2000; 376: 113-118.
 10. Aronson J. Torsky EA. External fixation of femur fractures in children. *J Pediatr Orthop.* 1992; 12:157-63. [Pub Med: 1552016].
 11. Krettek C, Haas N, Walker J, Tscherne H. Treatment of femoral shaft fractures in children by external fixation. *Injury.* 1991; 22:263-6. [Pub Med: 1937719].
 12. Bar-on E, Sagiv S. and Porat S. "External fixation or flexible intramedullary nailing for femoral shaft fractures in children". *J Bone and Joint Surg (Br)* 1997; 79-B: 975-8.
 13. KC Saikia, SK Bhuyan, T.D. Bhattacharya, S.P.Saikia, *Indian Journal of Orthopedics*, Oct 2010.
 14. Kalenderer O., Agus H and Sanli C. 'Open reduction and intramedullary fixation through minimal incision with ender nails in femoral fractures of children aged 6 to 16 years". *Acta Orthop Traumatol* June 2002; 36 (4): 303-9.
 15. Greisberg J., Bliss MJ., Ebersson CP., Solga P and d'Amato C. "Social and economic benefits of flexible intramedullary nails in the treatment of pediatric femoral shaft fractures". *Orthopedics* 2002; 25(10): 1067-70.
 16. Gross RH., Davidson R., Sullivan JA., Peeples RE. and Hufft R. "Castbrace management of the femoral shaft fracture in children and young adults". *Journal of Pediatric Orthopedics* 1983; 3 (5): 572-582.
-