

*International Journal of Scientific Research and Reviews*

**Non Syndromic Occurrence of true generalised Microdontia- A Report of two Unique and Rare Cases.**

**Y. Hemavathy Bhaskar\* and G.V.Murali Gopika Manoharan**

Tamilnadu Government Dental College and Hospital, Chennai-600003 Tamilnadu, India.

---

**ABSTRACT:**

Dental anomalies are the formative defects caused by genetic disturbance or environmental factors during tooth morphogenesis. Developmental defects occur either alone or in combination with other birth defects. Abnormalities in size and number of teeth are occasionally recorded. True generalised microdontia is a rare condition in which all teeth are smaller than normal. Microdontia can occur as true generalised, relatively generalised or involving single tooth. Generalised microdontia which is a rare phenomenon sometimes occurs in association with systemic conditions like pituitary dwarfism or Fanconi's anemia. This paper deals with two cases of generalised microdontia without any apparent systemic association.

**KEY WORDS:** Morphogenesis, Pituitary dwarfism, Fanconi's anemia, microdontia

---

**\*Corresponding Author:**

**Y.Hemavathy Bhaskar**

Pg student, Department of Oral medicine and Radiology,

Tamilnadu govt. Dental College and Hospital,

Chennai.600003, Tamilnadu

Email id: [hema.baskar87@gmail.com](mailto:hema.baskar87@gmail.com)

Phone No: 9445875543

## **INTRODUCTION:**

Microdontia is a rare phenomenon. The term microdontia is defined as the condition of having abnormally small teeth. According to Boyle, Microdontia, ‘the teeth are small, the crowns are short and normal, contact areas between the teeth are frequently missing’<sup>1</sup>. Microdontia is divided into 3 types – true generalised microdontia, relative generalised microdontia, microdontia involving single tooth<sup>2</sup>.

The syndromes associated with Microdontia are Gorlin-Chaudhry-Moss syndrome, William’s syndrome, chromosomes d/u, 45x (Ullrich – Turner syndrome), chromosome 13 (Trisomy 13), Rothmund- Thomson syndrome, Hallermann-Shrieff, Orofacial Digital syndrome (Type-3), Oculo-Mandibulo-Facial syndrome, Trico-Rhino-Phalangeal, Type-1 Branchio-Oculo-Facial syndrome<sup>3</sup>. Dens evaginatus is a developmental malformation of crown shape occur in the early stages of dental development before the mineralization of hard tissues.

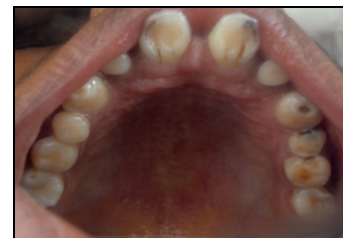Systemic anomalies associated with dens evaginatus are Rubinstein-Taybi syndrome, Mohr syndrome, Oro-Facial-Digital Type- 2 syndrome, Struge-Weber syndrome( Encephalo-Trigeminal Angiomatosis), Ellis Van Crevald syndrome<sup>4</sup>. This article discuss about two rare cases of generalised microdontia in which one case was associated with dens evaginatus in lower second molar teeth.

## **CASE SCENARIO – 1**

An 18 year old girl reported to the Department of Oral Medicine and Radiology with chief complaint of forwardly placed upper front teeth. Family history revealed that she was born out of consanguineous marriage. None of the family members were found to have similar features. On general examination, patient was healthy, moderately nourished and moderately built. No significant abnormalities were noticed in skeleton, skin, hair, nail, eyes, and ears. (Fig.1)

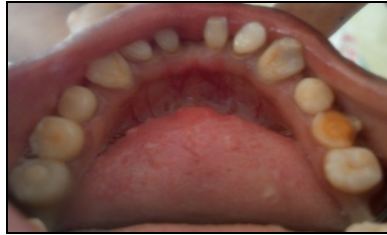

**Fig.1** Extraoral frontal view of the patient

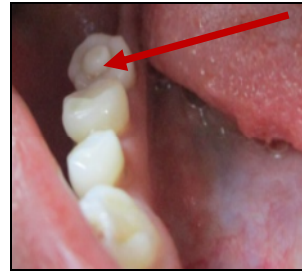


**Fig.2** Intraoral view maxilla

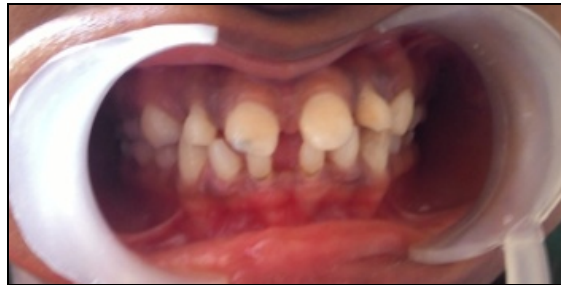Intra- oral examination revealed missing – 12,22, (with retained deciduous 52,62- Fig 2,3) 17,27,37,47. All the remaining teeth were smaller than the average size in permanent dentition, occlusal tuberculated projection in 46( Fig .4), proclined upper anteriors with spacing, increased over jet and overbite, , class -1 molar relation on right and left side.(Fig .5) Almost all the teeth did not have lingual pit. The posterior teeth were also small and exhibited a short occluso-gingival dimension.



**Fig.3 Intraoral view mandible**

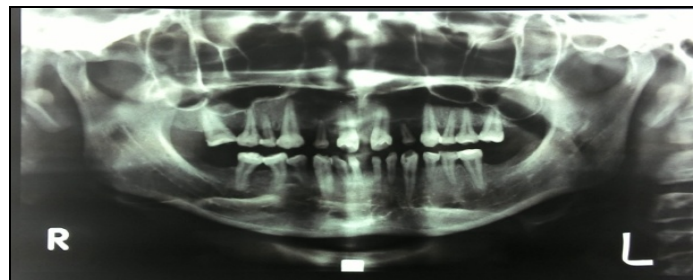


**Fig.4 lower first molar shows Dens evaginatus**



**Fig.5 occlusion of the patient**

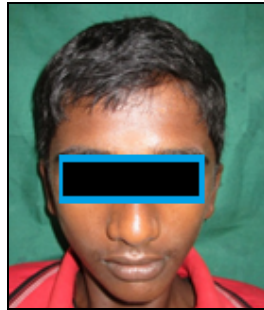OPG revealed mesio-distal diameter of all the teeth was smaller than the normal adult tooth size, retained deciduous 52,62 and no evidence of permanent tooth bud in 12,22,17,27,37,47.(Fig.6)



**Fig.6 OPG shows conical tooth root**

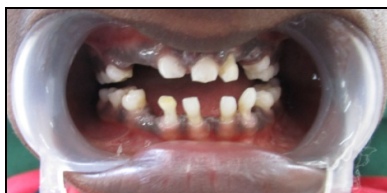## **CASE SCENARIO 2:**

A 15 year old boy reported to the Department of Oral Medicine and Radiology with chief complaint of small teeth. Family history revealed that he was born out of consanguineous marriage. None of the family members had similar features.

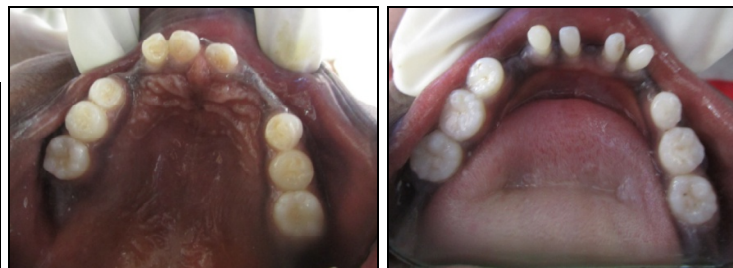

**Fig.7 extra oral view of the patient**

History revealed no exfoliation of primary teeth. No significant abnormalities were noticed in skin, hair, nails, eyes and ears (Fig.7) however intra-oral examination revealed open bite in the anterior region and improper contacts between the upper and lower molars. All deciduous teeth appear retained except missing counter parts of 12, 13 and all permanent first molars are erupted. (Fig.8, 9, 10)

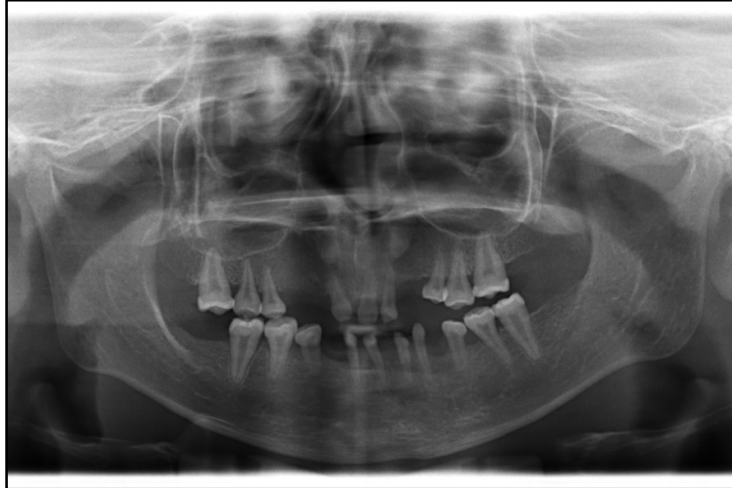

**Fig.8 occlusion of the patient**



**Fig.9&10 intraoral view maxilla and mandible**

OPG revealed no evidence of any developing tooth bud or impacted teeth (Fig.11).



**Fig.11 OPG shows conical tooth root**

By considering above mentioned features, in both cases and absence of significant abnormalities on systemic examination, diagnosis of Non-syndromic occurrence of true generalised microdontia was given.

## **DISCUSSION:**

Developmental dental anomalies constitute important category of dental morphology. Abnormalities in tooth size, shape and structure result from disturbance during morpho-differentiation stage of development<sup>5</sup>. The prevalence of this condition ranges from 0.8% to 8.4% in various populations<sup>6</sup>. Their incidence and degree of expression can provide important information for genetic studies. It can also help in understanding difference within and between populations<sup>7</sup>

Development of tooth has been shown to have ectodermal, mesodermal, and neural crest contributions. The variation in size of a particular tooth arises during the period when the form of the tooth is being determined by the enamel organ and the sheath of Hertwig at the bell stage of enamel organ. The determination of the form of the crown is thought to be related to different regions of the oral epithelium or to the ectomesenchyme. Studies have shown that different regions of the oral epithelium rather than the underlying ectomesenchyme are initially responsible for the shape of the crown<sup>3</sup>. Disturbance in morphodifferentiation may affect the form and size of the tooth leading to microdontia.

The cases, presented here seem to have severe microdontia involving both primary and permanent dentition. Treatment options for generalised microdontia include Orthodontic treatment, if arch-length discrepancy existed. Prosthodontic reconstruction such as crown and bridge may be

essential to improve esthetics<sup>8</sup>. In case 1, due to proclination of upper anteriors orthodontic treatment was planned, after extraction of retained deciduous teeth. Whereas, in case 2, extraction of upper and lower retained deciduous anteriors was advised followed by prosthetics replacement of teeth.

Dens evaginatus is a developmental anomaly characterised by a projection of enamel and dentin that usually encloses pulp tissue. The occurrence of Dens Evaginatus (DE) varies between one and four percent with a higher prevalence among people of Asian origin and is rare in white populations. It occurs in both primary and permanent dentitions, more frequently involving the mandibular premolars and rarely the molars, canines, incisors, and supernumerary teeth. It is five times more common in mandibular premolars<sup>9</sup>. In case 1, dens evaginatus in molar was evident.

A multifactorial etiology combining both genetics and environmental factors has been suggested for the formation of dens evaginatus<sup>10</sup>. Mutations in the human EDA1, EDAR, and EDARADD genes often result in more severe phenotypes resulting in tooth loss and malformation<sup>11</sup>.

The treatment options for dens evaginatus include pulp vitality preservation, caries preservation, elimination of tongue irritation, meeting esthetic and occlusal requirement.<sup>12</sup>

As the patients did not show any abnormal systemic manifestations, the entire syndromes associated with the dental anomalies were ruled out. The simultaneous presence of dens evaginatus and the generalized microdontia is very rare. Such unusual nature of dental anomaly has not been reported so far in the literature.

## **CONCLUSION:**

The dental finding seen in this case is rare. The cases had no relevant family history. Dens evaginatus deserves clinical importance as it provides chances of early pulp pathosis. Early and correct diagnoses of dental abnormalities are essential to preserve vitality of pulp. Variation in clinical manifestations of syndromic and non-syndromic occurrence of dental anomalies is challenging and could be an area for further research.

## **REFERENCES:**

1. Anita Singhal, Parul Singhal, Ranjan Gupta, and Kush Dev Jarial : True generalized microdontia and hypodontia with Spondyloepiphyseal dysplasia : Case reports in Dentistry : 2013; 4.

2. Santhosh Patil, NidhiYadav, Prashant Patil.:Non-Syndromic Occurrence of Multiple Dental and Skeletal Anomalies: A Rare Case Report and Brief Literature Review, *Journal of Clinical and Diagnostic Research*. 2012;8(7): ZD28-ZD3028 28.
3. Seema D Bargale and Shital DP Kiran. Non-syndromic occurrence of true generalized microdontia with mandibular mesiodens - a rare case. *Head & Face Medicine*: 2011; 7(1): 19.
4. Juan J. Segura-Egea, Alicia Jiménez-Rubio, José V. Ríos-Santos, Eugenio Velasco-Ortega: Dens Evaginatus of anterior teeth (talon cusp): Report of five cases, *Quintessence int*. 2003; 34:4.
5. Suprabha BS, Sumanth KN, Boaz K, George T. An unusual case of non-syndromic occurrence of multiple dental anomalies. *Indian J Dent Res*.2009; 20: 3.
6. Shalini Gupta , Kavita Nitish Garg , Amay Tripathi , and Om Prakash Gupta : Distribution of Various Developmental Dental Anomalies in Uttar Pradesh: A Hospital Based Study. *Research and reviews: journal of dental sciences* : 2014; 2: 3.
7. Shalini gupta, kavita Nitish Garg, O.P Gupta, Anurag Tripathi : Non – syndromic true localized microdontia of permanent central incisor- a case report. *Indian journal of dental sciences*, 2012; 4: 5.
8. Gregory W A: A case of extreme microdontia: oral surg oral med oral pathol : 1990:69 : 658
9. S. Stecker and A. J. DiAngelis, “Dens evaginatus: a diagnostic and treatment challenge,” *The Journal of the American Dental Association*, 2002; 133(2):190–193.
10. A. Sharma, “Dens evaginatus of anterior teeth (talon cusp) associated with other odontogenic anomalies,” *Journal of Indian Society of Pedodontics and Preventive Dentistry*, 2006; 24, supplement 1, S41–S43.
11. S. V. Nirmala, R. Challa, L. Velpula, and S. Nuvvula, “Unusual occurrence of accessory central cusp in the maxillary second primary molar,” *Contemporary Clinical Dentistry*: 2000; 2(2): 127–130.
12. M Guna shekhar , S Vijay kumar , J Tenny , G R Ravi: Conservative management of Dens evaginatus : Report of two unusual cases: *international journal of clinical pediatric dentistry* 2010; 3(2): 121-124.